

Case Report

A cervical sympathetic chain schwannoma of the left parapharyngeal space, presenting in the prestyloid region

Manish Gupta^{1*}, Sunder Singh¹, Monica Gupta², Rupinder Kaur³

¹Department of ENT, Gian Sagar Medical College & Hospital, Ramnagar, Banur, Patiala, Punjab, India

²Department of Medicine, Gian Sagar Medical College & Hospital, Ramnagar, Banur, Patiala, Punjab, India

³Department of Pathology, Gian Sagar Medical College & Hospital, Ramnagar, Banur, Patiala, Punjab, India

Received: 11 January 2016

Accepted: 04 February 2016

*Correspondence:

Dr. Manish Gupta,

E-mail: manishgupta1217@gmail.com

Copyright: © the author(s), publisher and licensee Medip Academy. This is an open-access article distributed under the terms of the Creative Commons Attribution Non-Commercial License, which permits unrestricted non-commercial use, distribution, and reproduction in any medium, provided the original work is properly cited.

ABSTRACT

Extracranial schwannomas in the head and neck region are rare neoplasms. The tumours often present as asymptomatic, slowly enlarging lateral neck masses. Though the computed tomogram criteria for differentiating vagal and sympathetic chain schwannoma is acceptable in most cases, but rarely the clinician may be misled in very large schwannoma of sympathetic chain where determination of the nerve of origin may be impossible until surgical exploration.

Keywords: Schwannoma, Parapharyngeal space

INTRODUCTION

The tumors of the parapharyngeal space account for only 0.5% of all the head and neck tumors.¹ Approximately 50% of the tumors have a salivary origin, 20% are neurogenic and the remaining 30% are represented by tumors such as benign and malignant lymphoreticular lesions, metastatic lesions and carotid body tumours. Schwannomas, also known as neurilemoma or neurinomas are benign nerve sheath neoplasms. About 25% to 45% of schwannomas are located in the head and neck and may involve the cranial nerves such as IV, V, VII, X, XI, XII or the sympathetic and peripheral nerves.² About 10% of schwannomas that occur in the neck region originate from the vagus or sympathetic nervous system.³ Pre-operative computed tomography (CT) or magnetic resonance imaging (MRI) are used to distinguish its origin, while open biopsy is not recommended due to associated complications like haemorrhage, infection and cranial nerve damage.⁴

CASE REPORT

A 65 year female, presented with gradually progressive difficulty in swallowing, predominantly to solid food since five months. There was a noticeable change in her voice quality for five months with occasional cough on taking meals. She had also observed a left upper lateral neck swelling which was progressively increasing in size for the last one month.

Examination revealed 2cm x 2cm left retro mandibular non-tender, non-pulsatile, firm mass that was not moving during deglutition or in longitudinal/ transverse planes. The examination of the oropharynx revealed 5cm x 4cm smooth, firm, non-inflamed mass pushing left lateral pharyngeal wall medially, substantially compromising the oropharyngeal space. The indirect laryngoscopy was not possible because of presence of mass hence, the patient was subjected to Hopkin's rod (90° telescope) examination and the bilateral true vocal cords were found to be normally functioning. Other cranial nerve

examinations were normal and there was no Horner's syndrome.

The CECT neck was done and it showed a well-defined, oval (6.7cm x 4.3cm x 4.0cm) soft tissue mass with mildly enhancing and areas of necrosis in the left parapharyngeal space (Figure 1). The mass was seen extending vertically from the level of the hard palate till the epiglottis inferiorly and bulging as well as compromising the oropharyngeal passage (Figure 2). The visualized vascular structure of the neck were slightly displaced posterolaterally with normal calibre and no distortion by the mass lying in left parapharyngeal space anteromedial to major vessels. The routine blood and urine investigations were normal. MR sagittal T1-weighted images confirmed a low intensity mass in the upper left neck with heterogeneous enhancement after contrast medium administration. Coronal T2-weighted confirmed displacement of major vessels postero-laterally without separation. A fine needle aspiration cytology (FNAC) was performed via the neck and it was suggestive of schwannoma.

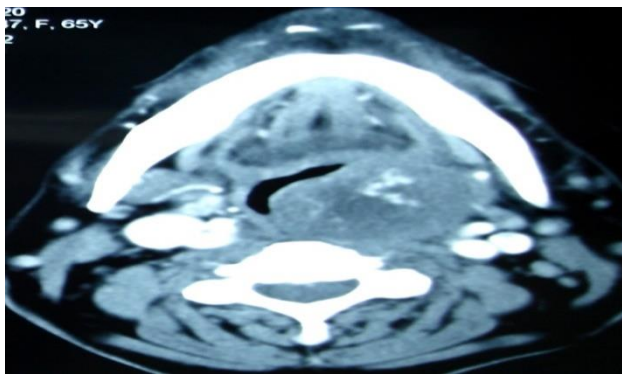


Figure 1: Axial section of CECT, showing a soft tissue mass in left parapharyngeal space with areas of vascularity and necrosis, pushing major vessels posterolaterally.

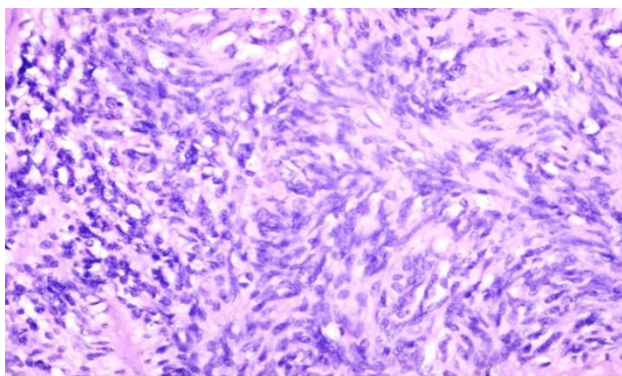


Figure 2: Coronal section CECT, showing vertical and horizontal extensions of the mass, compromising the oropharynx.

The initial clinical impression included other differentials such as paraganglioma, branchial cleft cyst, malignant

lymphoma and metastatic cervical lymphadenopathy. However there were certain points against each one of the conditions mentioned above. The metastatic lymph nodes are often multiple, with an evident primary, making the diagnosis easy. However, a solitary metastatic node from an unknown primary cancer may be difficult to differentiate from a schwannoma in the absence of periadenitis or extra nodal extension of disease.⁵ Paragangliomas show early arterial enhancement on CT, they are hypervascular lesions, while schwannomas are hypovascular.⁶ Deep lobe parotid tumors, lipomas and lymphadenopathy are usually seen arising in pre-styloid compartment; moreover the loss of the fat line between the mass and the parotid gland suggests a deep lobe parotid origin. Thus, in differentials of parapharyngeal space radiology (CT, MRI) plays the key role, by not only identifying the tumour but also its relation with surrounding vascular, muscles and neural structures.⁷ Carotid body tumour typically splays the carotid bifurcation. Angiography is indicated if the mass is contrast enhancing and if major vessels appear to be compressed by the tumour. When a vagal schwannoma is enlarged, the internal jugular vein (IJV) is displaced laterally, and the internal carotid artery (ICA) is displaced medially while this separation of two structures is not seen in sympathetic schwannoma which displaces both the IJV & ICA anteriorly or anterolaterally.^{2,7}

The determination of nerve of origin in a parapharyngeal space schwannoma by imaging preoperatively is important for effective counselling regarding the expected sequel of surgical resection.

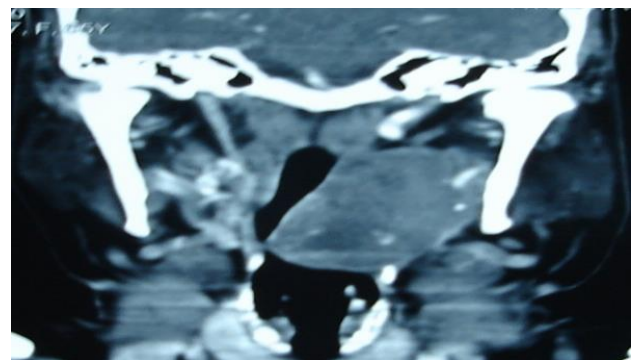


Figure 3: The histopathology image showing highly cellular (Antoni A) and sparsely cellular (Antoni B) areas comprising spindle shaped cells arranged in interlacing fascicles showing nuclear palisading (H&E stain, 40X).

Patient was taken up for excision of left parapharyngeal mass via transcervical approach under general anaesthesia. After excising left submandibular gland the tumour was identified arising from cervical sympathetic chain and intracapsular blunt dissection was done all around the tumor to separate the mass preserving the nerve. The histopathology confirmed a schwannoma with highly cellular (Antoni A) and sparsely cellular (Antoni

B) areas comprising spindle shaped cells arranged in interlacing fascicles showing nuclear palisading (Figure 3). In between compact rows of well aligned nuclei the Verocay body formation by the cell processes was also seen with areas of necrosis in between.

There was no recurrence and no nerve deficit noted in one year post-operative follow-up.

DISCUSSION

Schwannomas are typically seen between fourth and sixth decade of life, with female preponderance.³ Clinically they often present as an asymptomatic mass and any neurogenic symptom or sign may be related to the nerve of origin.³ In our case the difficulty in swallowing and hoarseness was not due to the neurological deficit but due to the mass effect.

As per the criteria suggested for identification of the nerve of origin, the cervical sympathetic chain runs posterior to the carotid sheath in the parapharyngeal space and is expected to displace the major vessels anteriorly.⁷ The modification in these criteria suggests that the large tumour arising from the sympathetic chain can distort the surrounding anatomy enough to displace the vessels together posteriorly and slightly laterally.¹ Though the earlier teaching was that the posterolateral displacement of the carotid sheath structures is frequent in tumours arising from the trigeminal nerve in the prestyloid parapharyngeal space.⁸ In our case, a large tumour arising from sympathetic chain lying posterior to the carotid sheath, distorted the surrounding fascial planes and pushed the vessels in an unpredictable posterior direction.

The conservative approach of observation and follow-up may be tried in some cases because of slow growth and non-invasive nature of these tumours, but they may affect adjacent tissues by expansion and pressure effect and compromising the aero-digestive tract. Thus, surgery is the main treatment modality. Total extirpation of the tumour, with preservation of intact fascicles, is always the goal for surgical treatment of nerve sheath tumours. Recently intracapsular enucleation has been introduced to preserve the neurological function. This preserves the nerve fibres function more than 30% when compared to tumor resection with primary anastomosis.⁹ The neurological functions can also be monitored using a nerve stimulator or under a microscope in performing the intracapsular enucleation.² If it is impossible to find an adequate plane and is technically difficult to preserve the integrity of the nerve trunk, the involved segment may be respected and an end-to-end anastomosis performed using microsurgical techniques.¹⁰ Post-operative complications with total tumor resection including nerve fibres are vocal cord palsy, pharyngolaryngeal anaesthesia, aspiration and Horner's syndrome, which may be transient or permanent. Some controversy exists regarding higher recurrence rate with enucleation, but it is mainly the

partial resection which is associated with high recurrence.¹¹ However, further long term follow-up studies are required to compare the benefit/ loss ratio of the enucleation procedure.

Learning points

- Schwannoma is an uncommon neurogenic benign tumour, often slow growing and asymptomatic.
- Radioimaging is useful not only for preoperative diagnosis of schwannoma, but may also identify the nerve of origin and this helps in detailed counselling about possible outcome.
- Intracapsular enucleation is the preferred procedure, since it preserves the nerve and has lesser post-operative morbidity.

Funding: No funding sources

Conflict of interest: None declared

Ethical approval: Not required

REFERENCES

1. Saito DM, Glastonbury CM, El-Sayed IH, Eisele DW. Parapharyngeal space schwannomas: preoperative imaging determination of the nerve origin. *Arch Otolaryngol Head Neck Surg.* 2007;133(7):662-7.
2. Kim SH, Kim NH, Kim KR. Schwannoma in head and neck: preoperative imaging study and intracapsular enucleation for functional nerve preservation. *Yonsei Med J.* 2010;51(6):938-42.
3. Kang GC, Soo KC, Lim DT. Extracranial non-vestibular head and neck schwannoma: a ten year experience. *Ann Acad Med Singapore.* 2007;36(4):233-8.
4. Biswas D, Marnane C, Mal R, Baldwin D. Benign extracranial nerve sheath tumor of the skull base: postoperative morbidity and management. *Skull Base.* 2008;18(2):99-106.
5. Anil G, Tan TY. Imaging characteristics of schwannoma of the cervical sympathetic chain: a review of 12 cases. *Am J Neuroradiol.* 2010;31:1408-12.
6. Rao AB, Koeller KK, Adair CF. Paragangliomas of the head and neck: radiologic-pathologic correlation. *Radiographics.* 1999;19:1605-32.
7. Furukawa M, Furukawa MK, Katoh K, Tsukuda M. Differentiation between schwannoma of the vagus nerve and schwannoma of the cervical sympathetic chain by imaging diagnosis. *Laryngoscope.* 1996;106:1548-52.
8. Tom BM, Rao VM, Guglielmo F. Imaging of the parapharyngeal space: anatomy and pathology. *Crit Rev Diagn Imaging.* 1991;31:315-56.
9. Valentino J, Boggess MA, Ellis JL, Hester TO, Jones RO. Expected neurologic outcomes for surgical treatment of cervical neurilemmomas. *Laryngoscope.* 1998;108:1009-13.

10. Ford LC, Cruz RM, Rumore GJ, Klein J. Cervical cystic schwannoma of the vagus nerve: diagnostic and surgical challenge. *J Otolaryngol.* 2003;32:61-3.
11. Zbaren P, Markwalder R. Schwannoma of the true vocal cord. *Otolaryngol Head Neck Surg.* 1999;121:837-9.

Cite this article as: Gupta M, Singh S, Gupta M, Kaur R. A cervical sympathetic chain schwannoma of the left parapharyngeal space, presenting in the prestyloid region. *Int J Otorhinolaryngol Head Neck Surg* 2016;2:95-8.