

## Case Report

# An atypical case of rhinosporidiosis: a case report

Timna C. J.<sup>1\*</sup>, Chandrika D.<sup>2</sup>

Department of ENT, <sup>1</sup>Sanjeevani Multispeciality Hospital, Kollakadavu, Chengannur, Kerala, <sup>2</sup>Akshaya Hospital, Harihar, Davanagere, Karnataka, India

**Received:** 13 July 2018

**Revised:** 16 October 2018

**Accepted:** 17 October 2018

### \*Correspondence:

Dr. Timna C. J.,

E-mail: [jdrtimna@yahoo.com](mailto:jdrtimna@yahoo.com)

**Copyright:** © the author(s), publisher and licensee Medip Academy. This is an open-access article distributed under the terms of the Creative Commons Attribution Non-Commercial License, which permits unrestricted non-commercial use, distribution, and reproduction in any medium, provided the original work is properly cited.

## ABSTRACT

Rhinosporidiosis is an infective chronic granulomatous lesion caused by an organism *rhinosporidium seeberi*, which is seen endemic in some parts of Asia. This organism is difficult to culture and the diagnosis is based on histopathological examination. This disease is more commonly seen in men, in second to third decade.. This case report is regarding a case of a 55 years old lady with history of recurrent rhinosporidiosis in nose. The lesion was found to arise from the inferior meatus and was pale smooth glistening in appearance, insensitive and does not bleed on touch. Site of origin of the polyp and the appearance was atypical of that of rhinosporidiosis. Patient was subjected for endoscopic excision and cauterisation of the base of the lesion and sent for histopathological examination .Biopsy confirmed the diagnosis of rhinosporidiosis.

**Keywords:** Rhinosporidiosis, Histopathology

## INTRODUCTION

Rhinosporidiosis is a rare infective chronic granulomatous disease endemic in some parts of Asia and also other parts of the world, most commonly reported in India, Brazil and Srilanka.<sup>1</sup>

Causative organism of the disease is *rhinosporidium seeberi* and nature of the organism is enigmatic between a fungus and a protozoan. The organism can be visualised with gomori methenamine silver, periodic acid sheff as well as haematoxylin and eosin staining.<sup>2</sup>

It's a zoonotic disease and seen in cattle, horse, mule. Transmission is occurring through stagnant pools of water, dust from which endospore penetrates the nasal cavity mucosa and matures into sporangium in the submucosa. After maturation the sporangia bursts releasing endospores.

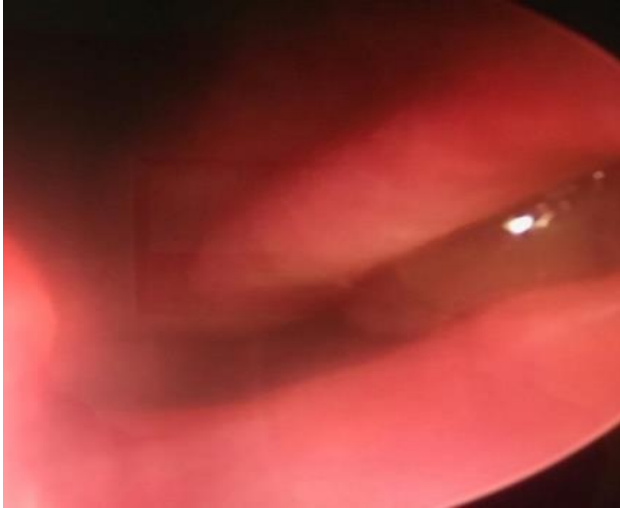
More commonly seen in males in the ratio of 3:1 (male to female) and most common sites of affection are nasal septum, nasal floor, and inferior turbinate. Primary site of affection is nose, also occurs in eye, urethra, genitalia.<sup>3</sup> Other common sites of affection are larynx, tracheobronchial tree, esophagus, conjunctiva, ears, maxillary antrum, parotid duct, external genitalia, urethra.

Patients with rhinosporidiosis may have one or more pedunculated pink to red coloured nasal masses with surface studded with white to yellow dots. Microscopy of the mass shows sporangia with endospores. Chronic inflammatory cells like lymphocytes, plasma cells and eosinophils.<sup>3</sup> Chance of recurrence is 10%. Treatment is surgical excision and frequent follow up are done.<sup>4</sup>

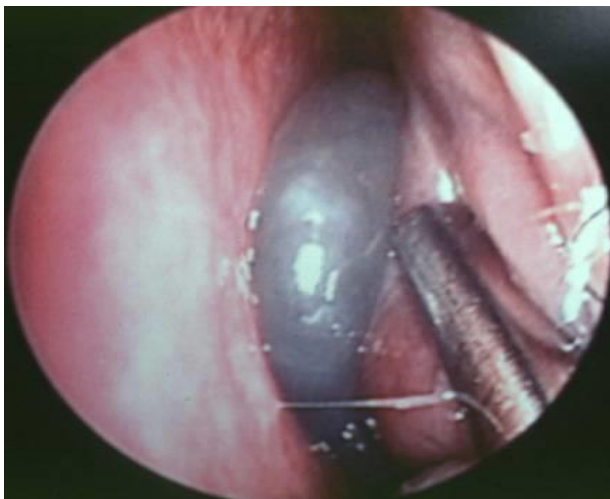
## CASE REPORT

55 years old female patient presented with history of bilateral nasal obstruction for the past 6 months. Patient was complaining of reduced hearing on the left side. No

complaints of headache, facial pain, mucoid discharge, excessive sneezing, postnasal drip or nasal bleed. History of 2 nasal surgeries in the past for the same complaints. Details were not available. No other significant past history.



**Figure 1: Polypoidal lesion seen in inferior meatus.**

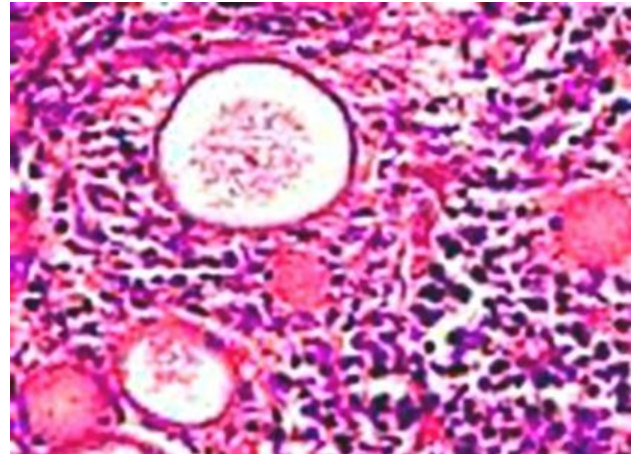


**Figure 2: Polypoidal lesion seen extending to the postreior nasal cavity.**

There was a pale glistening polypoidal mass lesion in the posterior choanal area which was found to be arising from inferior meatal area. Mass lesion was insensitive to touch, pale in nature and doesn't bleed on touch. In the other nasal cavity, septal synechiae seen.

Patient was advised CT scan of paranasal sinuses and no mass lesion in the sinuses or nasolacrimal duct except inferior turbinate on the left side was found to be bulky.

Patient was subjected for endoscopic surgery and was completely excised after inferior turbinoplasty. And base of the lesion was cauterised with bipolar diathermy. No excessive bleeding was noted during the procedure.



**Figure 3: Histopathology of rhinosporidiosis.**

Specimen sent for histopathological examination and the report came as rhinosporidiosis with several round to oval sporangia filled with endospores seen as shown in below picture.

Patient was followed up to 8 months and no recurrence was noted.

## DISCUSSION

Rhinosporidiosis is an infective chronic disease which was reported initially in Latin America over a century ago. It appears to be endemic in Indian subcontinent. It's a zoonotic disease spread via stagnant water pools and dust.<sup>5,6</sup> Patient initially presents with nasal obstruction, nasal bleeding, nasal itching, sneezing. In the present case nasal obstruction was the only complaint. In contrast with the inflammatory polyps arising from the middle meati, these polyps commonly arise from the anterior nares, nasal septum, inferior turbinate, floor of nose. In the present case the mass was found to arise from the inferior meatus.

The typical appearance of the mass is pink to red coloured pedunculated polyps with white dots and the mass usually bleeds on touch. In the present case the lesion was found to be pale smooth, glistening relatively avascular and insensitive and doesn't bleed on touch.

Histopathology of the lesion is the diagnostic criteria for rhinosporidiosis. Several sporangia, oval or round in shape filled with endospores bursting through its chitinous wall seen.<sup>7</sup> In this case histopathology was consistent with the diagnosis.

## CONCLUSION

Nasal rhinosporidiosis is an uncommon disease entity which may mimic neoplasm or allergic inflammatory polyp, but depending on the site of origin, irrespective of the clinical appearance should consider the differential diagnosis of rhinosporidiosis.

*Funding: No funding sources*

*Conflict of interest: None declared*

*Ethical approval: Not required*

## REFERENCES

1. Bruce M, Wenig, Richardson M. Modern surgical pathology (second edition); 2009: 473-476.
2. Ngamdu YB, Ngabda HA, Kodiya AM, Sandabe MB, Isa A, Garandawa HI. Nasal rhinosporidiosis a case report. 2014;4(1):26-8.
3. Burdak P, Joshi N, Nag BP. Nasal Rhinosporidiosis- A Case report, *Int J Basic Applied Med Sci*. 2015;5(1):304-7.
4. Welsch O, Vesay JV. Tropical dermatology (second edition); 2017: 6-13.
5. Brandwein M, Gansler, Walter C Bell. et al Head and neck pathology (second edition) 2013: 1-27.
6. Arseculeratne SN. Recent advances in rhinosporidiosis and rhinosporidium seeberi. *Indian J Med Microbiol*. 2002;20(3):119-31.
7. Dhingra PL, Dhingra S. Disease of ear, nose, and throat and head and neck surgery 6th edition; 2014: 158-159.

**Cite this article as:** Timna CJ, Chandrika D. An atypical case of rhinosporidiosis: a case report. *Int J Otorhinolaryngol Head Neck Surg* 2018;4:1502-4.