

## Original Research Article

# A retrospective review of complicated foreign bodies of upper aerodigestive tract

Ritesh Mahajan\*, Prashanth V.

Department of Otorhinolaryngology, Rajarajeswari Medical College and Hospital, Bangalore, Karnataka, India

**Received:** 01 December 2018

**Revised:** 13 February 2019

**Accepted:** 16 February 2019

**\*Correspondence:**

Dr. Ritesh Mahajan,

E-mail: [ritesh54mahajan@gmail.com](mailto:ritesh54mahajan@gmail.com)

**Copyright:** © the author(s), publisher and licensee Medip Academy. This is an open-access article distributed under the terms of the Creative Commons Attribution Non-Commercial License, which permits unrestricted non-commercial use, distribution, and reproduction in any medium, provided the original work is properly cited.

### ABSTRACT

**Background:** Inhalation/aspiration of foreign bodies (FB) into upper aerodigestive tract are very commonly encountered by otorhinolaryngologists. Most foreign bodies in adults are manageable, but sometimes can lead to fatal consequences in children. However, despite significant advances in instrumentation, they remain a therapeutic and diagnostic challenge. The aim was to study the clinical presentation, site of impaction, complications and management of foreign bodies in upper aerodigestive tract.

**Methods:** A retrospective study was conducted in department of ENT-Head and Neck Surgery, Rajarajeswari Medical College and Hospital, Bangalore. A total of 50 eligible patients were reviewed who got operated for foreign body in upper aerodigestive tract under general anaesthesia.

**Results:** History of foreign body was present in 86% of cases and 25% of the patients had complaints of difficulty in breathing. Nose being most common site in 74%, 70% of the patient belongs to 0-10 age group and male: female ratio was 1.7:1. Complications were seen in 12% of patients. Foreign body removal rate was 100%.

**Conclusions:** Early diagnosis is the key to successful and uncomplicated management of FB in upper aerodigestive tract. An orderly and systematic approach along with proper history and clinical examination is keystone in diagnosis and early management.

**Keywords:** Foreign body, Dysphagia, Nasal obstruction, Aerodigestive tract

### INTRODUCTION

Despite significant advances in prevention, first aid and endoscopic technology, foreign bodies of the upper aerodigestive tract in paediatric population remains a diagnostic and therapeutic challenge. Inhalation/aspiration of foreign bodies (FB) into upper aerodigestive tract are very commonly encountered by otorhinolaryngologists but sometimes it can lead to fatal consequences. It is estimated that 1500 deaths occur annually related to the ingestion of foreign materials and 3000 deaths occur annually due to complications of foreign material aspiration.<sup>1</sup> Special attention is to be given in cases of foreign bodies in esophagus and bronchus as they are the most difficult ones to identify

and retrieve. The specific manifestations of an FB in the esophagus depend on the type of FB, the site where it is lodged, the degree of obstruction, and the length of time between ingestion and evaluation.<sup>2</sup> In many children's recurrent pneumonia and upper respiratory tract infections, or conditions that do not respond to appropriate medical management in children should always raise the suspicion of an aspirated foreign body.<sup>3</sup>

#### *Aim and objectives*

The main aim was to study the clinical presentation, Site of impaction, complications and management of foreign bodies in upper aerodigestive tract.

**METHODS**

A retrospective study from May 2011 to May 2013 was conducted in department of ENT-Head and Neck Surgery, Rajarajeswari Medical College and Hospital, Bangalore. The data was retrieved from the medical records department with the permission of institutional ethical committee and collected data was analyzed using Microsoft excel.

A total of 50 eligible patients were reviewed who got operated for foreign body in upper aerodigestive tract.

**Inclusion criteria**

Patients of any age group presented with or without history of swallowing, inserting or inhaling foreign bodies with symptoms like dysphagia, drooling of saliva, stridor, wheeze and acute respiratory distress were included in the study.

**Exclusion criteria**

Those patients in whom foreign body was removed in the minor operation theatre without any sedation were excluded from the study. Foreign bodies passing beyond oesophagus and foreign body in the lung tissue were not included in the study.

**Procedure**

All the procedures were performed under general anesthesia. For nasal foreign bodies in most of the cases 0 degree nasal endoscope was used to visualize the foreign body and removed with the help of Tilley’s forceps and

curved probe, similarly for the digestive tract foreign bodies’ rigid oesophagoscope was used and for the bronchial foreign bodies both rigid and flexible bronchoscopes were used for the removal of foreign bodies.

**RESULTS**

Cases were categorized as nasal foreign bodies, digestive tract foreign bodies and airway foreign bodies. Analysis of positive cases revealed the following observations.

**Gender**

A total of 50 patients were included in the study out of which 35 patients were male and 15 patients were female.

**Age of the patient**

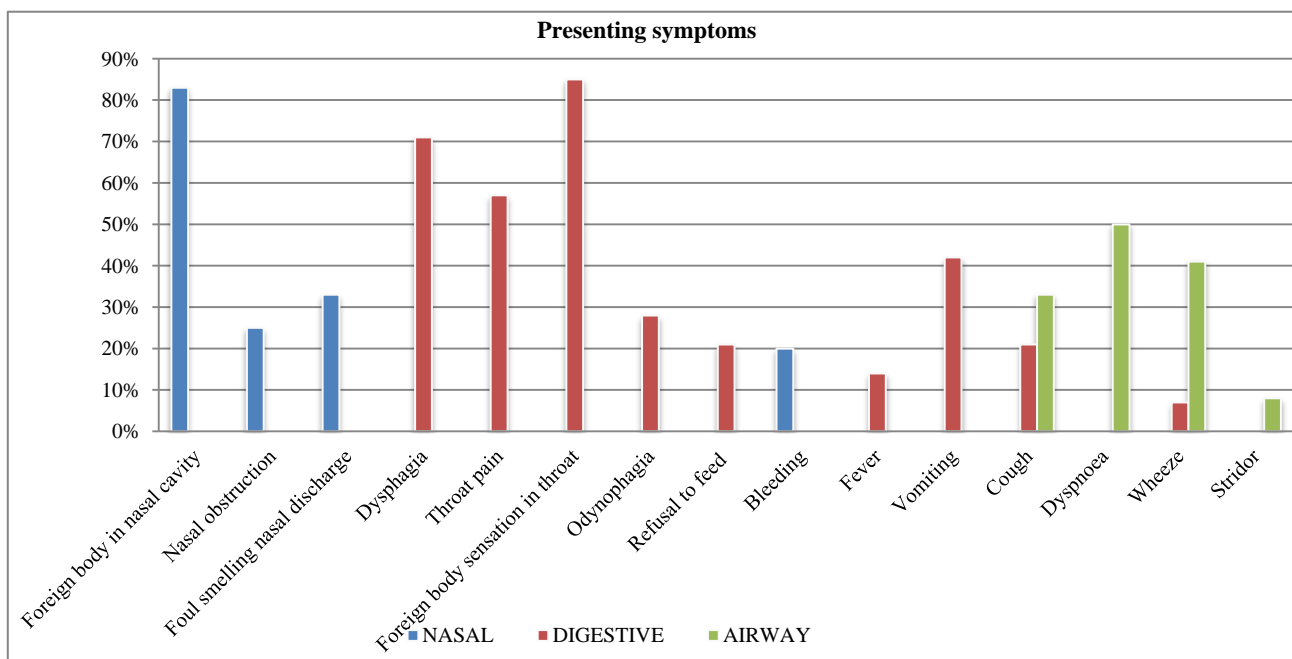
Most of the patients were in age group of 1-5 years i.e. 20 patients, 15 patients were in age group of 5-10 years, 6 patients were in age group of 10-15 years and rest of the patients i.e. 9 patients were in age group of 15-30 years.

**Percentage**

In our study nasal foreign bodies were seen in 48% of the patients, airway foreign bodies were found to be in 28% of the patients and 24% of the patients presented with digestive tract foreign bodies.

**Signs and symptoms of presentation**

Illustrated in Figure 1 and 2.



**Figure 1: Presenting symptoms.**

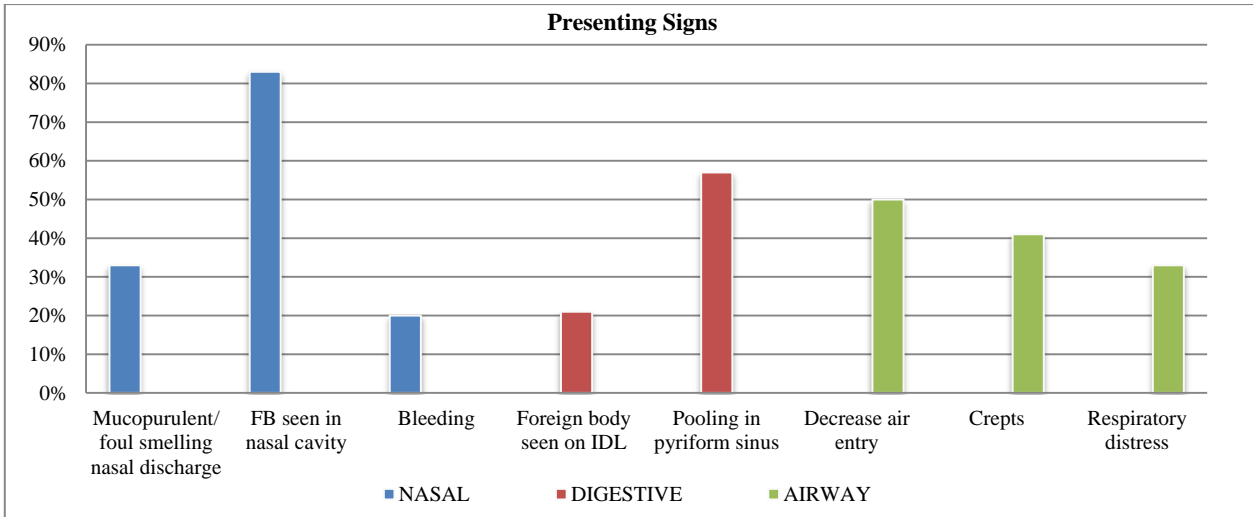


Figure 2: Presenting signs.

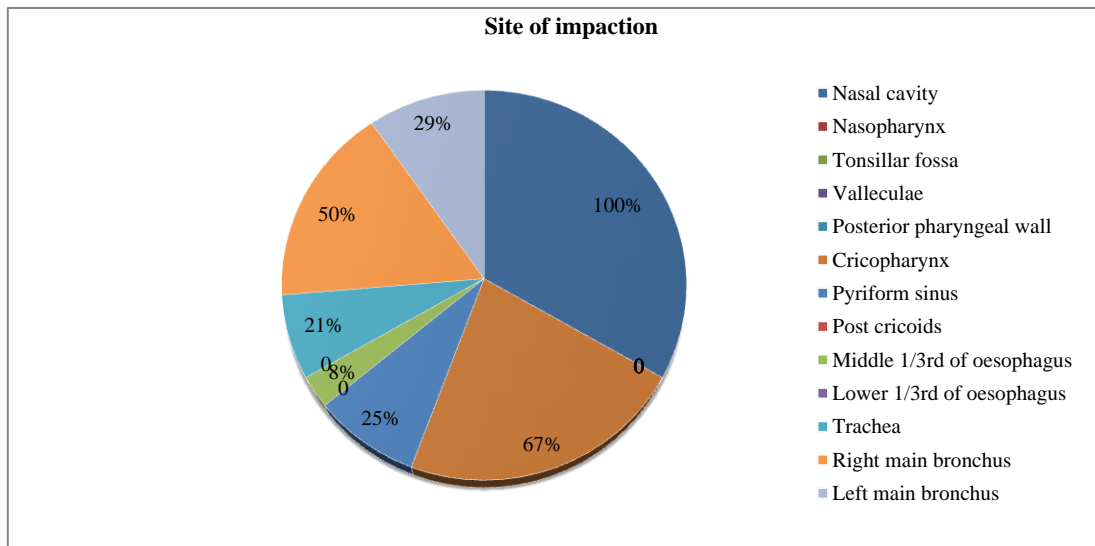


Figure 3: Site of impaction of foreign bodies.

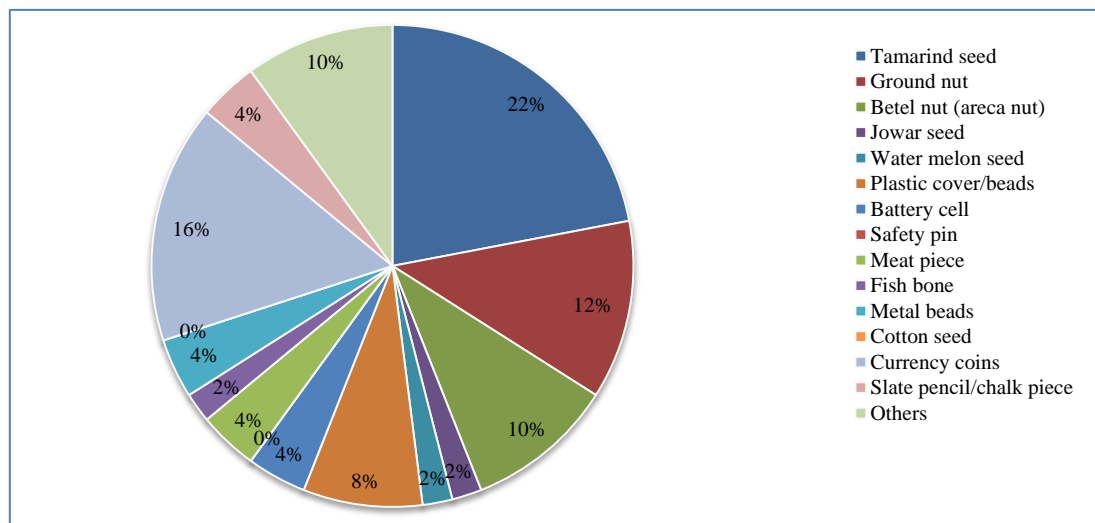


Figure 4: Types of foreign bodies.

### **Site of foreign body**

The most common site of foreign body impaction was nasal cavity (33%), cricopharynx was the second most common site (22%), and the third most common site was right main bronchus (17%). Other sites of foreign body impaction are depicted in Figure 3.

### **Nature of foreign body**

Vegetative foreign bodies were seen in 54% of the patients and non vegetative foreign bodies were seen in the 46% of the patients.

### **Complications**

Nasal bleeding was the most common complication that was encountered in 3 patients, other complications encountered were; septal perforation, mucosal injury in nasal cavity, pneumonia and bronchospasm.

## **DISCUSSION**

Foreign body in the airway constitute a medical emergency and requires immediate attention, the basic principles of their extraction were meticulously developed by Jackson, whose concepts of the mechanical problems encountered and demonstration of their solutions are responsible for keeping morbidity and mortality at minimum.<sup>1</sup> Koempel et al in their clinical study stated that commonest symptoms are drooling of saliva, dysphagia, poor feeding and vomiting.<sup>2</sup>

### **Age of presentation**

In our study of foreign bodies in aerodigestive tract about 20% of the patients were 1-5 years. This is similar to Lemberg et al review of patients treated over a 5-year period in which 17% of the patients were 5 years of age or older.<sup>4</sup> These data suggest that older children and adolescents represent a distinct group of patients at risk for foreign body accidents.

### **Types of foreign body**

*Nasal foreign bodies:* In our study we encountered a wide range of foreign bodies, of which tamarind seed 25% and ground nut 13% were the most common found foreign bodies in the nasal cavity. In total, 54% of the cases were vegetative foreign bodies and 46% were non-vegetative.

*Digestive tract foreign bodies:* Currency coins 67% were the most common followed by meat piece 17% in our study. Fish bone and other substances were also encountered. Hawkins in his paper on 246 oesophagoscopies performed over a 19-year period to remove blunt oesophageal foreign bodies reported that 81% of the foreign bodies were coins which correlate with our study.<sup>5</sup>

*Airway foreign bodies:* In our study, tamarind seed 36% was the most common, followed by ground nut 21% along with betel nut 21%. In Banerjee, et al's an analysis of the management of 223 children with laryngo-tracheobronchial foreign bodies 168 cases (66.4%) of the recovered foreign bodies were organic in origin, the majority of them being peanuts which is similar to our study.<sup>6</sup>

### **Site of foreign body**

*Nasal cavity foreign bodies:* 96% of the cases were unilateral cases in our study; foreign body in right nasal cavity was 50% and 46% in the left nasal cavity.

*Digestive tract foreign bodies:* In our study 67% of the cases, foreign bodies were in Cricopharynx, 25% were in pyriform sinus. In a study by Shivakumar et al, of the total number of 152 patients, most of blunt foreign bodies in children 83.5% were impacted in post cricoid region whereas in adults, the foreign bodies 37.5% were seen in upper esophagus which correlates with our study.<sup>7</sup>

*Airway foreign bodies:* In our study, right main bronchus constituted 50% followed by left main bronchus. In a retrospective review of 400 Chinese children who had inhaled foreign bodies was undertaken, the majority of the foreign bodies were found most often in right bronchial tree (46%) which is similar to our study.<sup>8</sup> In Banerjee et al analysis of the management of 223 children with laryngo-tracheobronchial foreign bodies it was found that in 105 cases (47.1%) were seen in right bronchial tree.<sup>6</sup>

### **Management**

*Nasal foreign bodies:* Majority of the cases 93% were managed using 0<sup>0</sup> karlstorz nasal endoscope with Jobson Horne probe, remaining 7% were removed with the help of suctioning and Tilley's nasal dressing forceps. Nandapalan, McIlwain, et al's study of 134 children with nasal foreign bodies concluded that if the foreign body was close to anterior nares, it can be removed with standard instruments.<sup>9</sup>

*Digestive tract foreign bodies:* In all the 12 cases we studied, alligator forceps were used to remove the foreign bodies irrespective of the type. Hawkins in his paper on 246 oesophagoscopies performed over a 19-year period to remove blunt oesophageal foreign bodies, reports oesophagoscopy as the best method for removal of all esophageal foreign bodies.<sup>5</sup> Shivakumar et al study on ingested foreign body endoscopic removal of foreign body was done under general anesthesia for all cases.<sup>7</sup>

*Airway foreign bodies:* In all the cases we studied, bronchoscopy was used for removal of all airway foreign bodies as all the cases had foreign bodies in either of the bronchus. In Banerjee et al's analysis of the management of 223 children with laryngo-tracheobronchial foreign

bodies, endoscopic removal was possible in all but 9 cases which are similar to our study.<sup>6</sup> In a retrospective study by McGuirt et al, Rigid endoscopy under general anesthesia was the preferred method for removal of the aspirated material.<sup>10</sup>

## CONCLUSION

Foreign bodies in the upper aerodigestive tract are a common clinical problem in otolaryngological practice as evident in this study. Symptoms of foreign bodies in the aerodigestive tract are mainly non-specific and needs high degree of suspicion, experience and clinical acumen. Signs are also variable from case to case and inconstant in a particular case. However the only single reliable factor is a positive history which often is not contributory in spite of careful and tactful attempt to elicit it and particularly in children where it goes unnoticed. An orderly and systematic approach along with proper history and clinical examination is keystone in diagnosis and early management.

## ACKNOWLEDGEMENTS

The authors would like to thank Department of Otorhinolaryngology, Rajarajeswari Medical College and Hospital, Bangalore, Karnataka, India.

*Funding: No funding sources*

*Conflict of interest: None declared*

*Ethical approval: Not required*

## REFERENCES

1. Holinger LD. Foreign Bodies of the Airway and Esophagus. In: Holinger LD, Lusk RP, Green CG, eds. Pediatric Laryngology and Bronchoesophagology. Philadelphia: Lippincott-Raven Publishers; 1997: 233-251.

2. Koempel JA, Holinger LD. Foreign bodies of the upper aero digestive tract. Indian J Pediatr. 1997;64:763-9.
3. Harris CS, Baker SP, Smith G, et al. Childhood asphyxiation by food: a national analysis and overview. JAMA. 1984;251(17):2231-5.
4. Lemberg PS, Darrow DH, Holinger LD. Aerodigestive tract foreign bodies in the older child and adolescent. Ann Otol Rhinol Laryngol. 1996;105:267.
5. Hawkins DB. Removal of blunt foreign bodies from the esophagus. Ann Otol Rhinol Laryngol 1990;90:935.
6. Banerjee S. Concept of foreign body its past and present. Int J Otolaryngol Head Neck Surg. 1999;51(Suppl 1):23-30.
7. Shivakumar AM, Naik, Prashanth KB, Hongal GF, Chaturvedy. Foreign bodies in upper digestive tract. Indian J Otolaryngol Head Neck Surg. 2006;58(1):63-90.
8. Mu L, He P, Sun D. Inhalation of foreign bodies in Chinese children: A review of 400 cases. Laryngoscope. 1991;101:657-60.
9. Nandapalan V, McIlwain JC. Removal of nasal foreign bodies with a Fogartybiliary balloon catheter. J Laryngol Otol. 1994;108:758-60.
10. McGuirt WF, Holmes KD, Feehs R, Browne JD. Winston-Salem. Tracheobronchial foreign bodes. Laryngoscope. 1988;98:615-7.

**Cite this article as:** Mahajan R, Prashanth V. A retrospective review of complicated foreign bodies of upper aerodigestive tract. Int J Otorhinolaryngol Head Neck Surg 2019;5:734-8.