

## Original Research Article

DOI: <http://dx.doi.org/10.18203/issn.2454-5929.ijohns20193878>

# Swimmer's ear: how does ear canal pave its way from 'sensitivity to septicity'?

Venkatesh Ballal, Sphoorthi Basavannaiah\*

Department of ENT, Subbaiah Institute of Medical Sciences, Shimoga, Karnataka, India

**Received:** 16 May 2019

**Revised:** 04 July 2019

**Accepted:** 11 July 2019

### \*Correspondence:

Dr. Sphoorthi Basavannaiah,

E-mail: [sphoorthi86@rediffmail.com](mailto:sphoorthi86@rediffmail.com)

**Copyright:** © the author(s), publisher and licensee Medip Academy. This is an open-access article distributed under the terms of the Creative Commons Attribution Non-Commercial License, which permits unrestricted non-commercial use, distribution, and reproduction in any medium, provided the original work is properly cited.

## ABSTRACT

**Background:** Otitis externa is a condition that causes inflammation of the external ear canal. It is estimated that around 1 in 10 people will be affected by this condition at some point in their lives. It is relatively common in occurrence and is referred to as "swimmer's ear" because swimming in polluted water is a common way to contract it, but it is also possible from water trapped in the ear canal after a shower, especially in a humid climate. Hence, repeated exposure to water can make the ear canal more vulnerable to inflammation and infection. The aim of the present study is to find out the aetiology of this condition and also to educate the population regarding adapting and implementing measures so as to avoid the triggers that causes this condition.

**Methods:** 89 patients who consulted the ENT outpatient department were clinically evaluated and diagnosis was made and treated accordingly.

**Results:** As per the study, 79% patients in the infective group superseded 21% patients in the reactive group with the predominance of 58% patients with acute cases in terms of disease course and progression. 30% patients had repeated trauma to the ear canal as the common stimulant for the infection, that led to 25% patients with otomycosis as the commonest cause for otitis externa.

**Conclusions:** Ear canal infection ranges from simple irritation to severe inflammation and in either scenario it should not be ignored and overlooked upon.

**Keywords:** Ear canal, Infective, Otitis externa, Reactive

## INTRODUCTION

Otitis externa is the generalised condition of the skin in the external auditory canal characterised by general oedema and erythema associated with or without otorrhoea and reduced hearing acuity. It affects 1-3% of people in a year with >95% cases being acute. About 10% of people are affected at some point in their lives. It can occur at all ages but very common among children between 7 to 12 years of age and among elderly. It occurs with near equal frequency in males and females. It has more affection towards people who live in warm and wet climates.<sup>1,2</sup> The aim of this study is to find out the commonest cause of otitis externa at our set up, to trace the group inclination in the aetiology of the disease, to

note down the onset with duration of disease course with its progression among our patients, to categorise the disease based on its symptomatology and clinical presentation and to find out the commonest predisposing factors in the disease incidence and evolution. While objective is to educate the population to preclude and prevent any further untoward manifestation of this condition.

## METHODS

### Study design

The present study is a descriptive study.

### Place of study

The study was conducted at tertiary care hospital, Subbaiah Institute of Medical Sciences, Shimoga.

### Study period

The study was conducted for 1 year (from January 2018 to January 2019).

### Selection criteria

A random sample of 89 patients who consulted the ENT outpatient department with ear complaints were clinically evaluated.

### Inclusion criteria

- All the patients who presented with ear complaints were considered.
- No gender bias.
- Patients of all age groups were considered for the study.

### Exclusion criteria

- All other ear related diseases were excluded from the study.
- TMJ arthritis, foreign body ear, polyp arising from middle ear, exostosis, osteoma, any growth/mass in the ear canal was not considered in the sample size.

### Procedure of the study

A random sample of 89 patients who consulted ENT outpatient department with ear complaints over a period of 1 year was selected for the study. A thorough history with detailed clinical examination was done in all of them to evaluate the cause. The relevant investigations; if necessary were done to arrive at a diagnosis. Treatment was given based on the diagnosis which was mainly conservative line of management. Informed written consent was taken during the study period. Ethical clearance has been taken from Institutional Ethics Committee before the start of the study.

## RESULTS

Among 89 patients, 55 patients that is 62% had infection as a result of ear picking while rest 34 patients (38%) had other causes of otitis externa as shown above in exploded pie 3D representation.

Among 70 patients (79%) with infective aetiology, 46 (66%) patients that are had infection due to canal stimulation with external devices and rest 24 patients (34%) had other conditions.

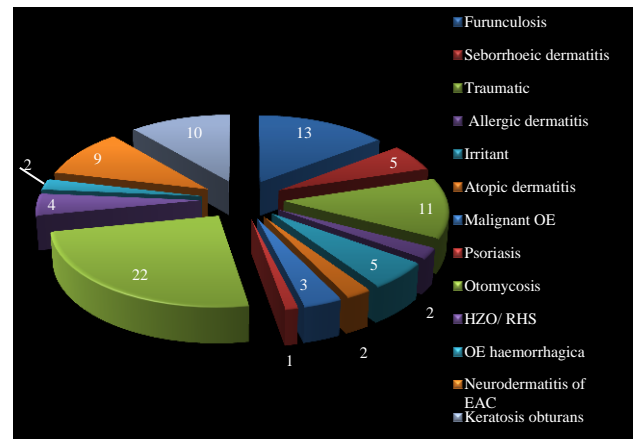


Figure 1: Causes of otitis externa.

Among them, 9 patients (47%) had neurodermatitis of ear canal due to chronic canal stimulation leading to everlasting itching and skin abrasion while rest 10 patients (53%) had other causes as depicted above in the diagram.

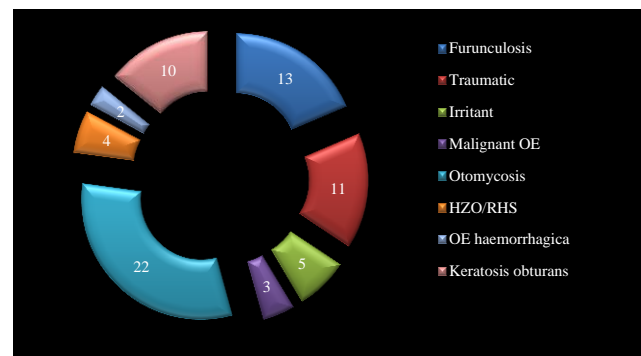


Figure 2: Distribution of patients based on infective aetiology.

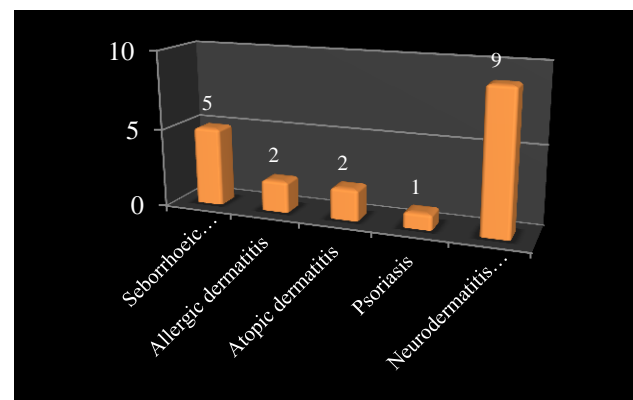
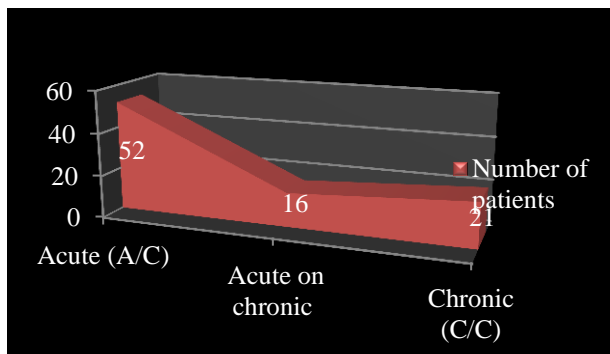


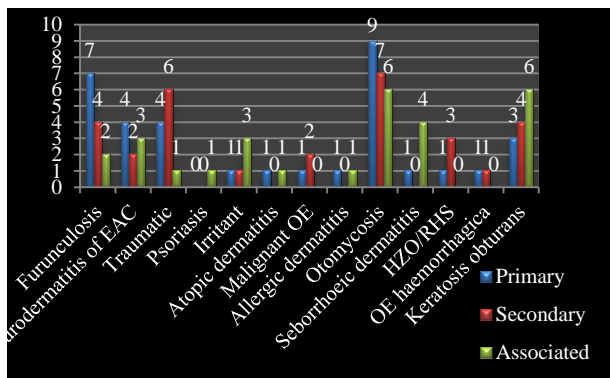
Figure 3: Distribution of patients based on reactive aetiology.

52 A/C are {11 furunculosis, 11 traumatic, 22 otomycosis, 4 HZO and 2 OE hemorrhagica} that is (58%). 16 A/C on C/C are {5 irritant dermatitis, 2 allergic dermatitis and 9 neurodermatitis of EAC} that is (18%). Rest 21 C/C are {3 malignant OE, 10 keratosis obturans,

5 seborrhoeic dermatitis, 2 atopic dermatitis and 1 psoriasis} that is (24%).

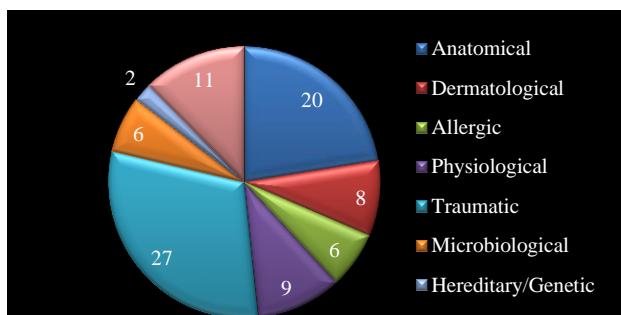


**Figure 4: Onset with duration of disease in all patients.**



**Figure 5: Symptom presentation in all the patients.**

34 patients (38%) with primary symptoms are represented in “blue” (ear discharge and decreased hearing), 30 patients (34%) with secondary symptoms are represented in “red” (otalgia) and 25 patients (28%) with associated symptoms are represented in “green” (itching and aural fullness).



**Figure 6: List of predisposing factors associated with otitis externa.**

27 patients (30%) have traumatic as the triggering factor. Anatomical: furunculosis (6), otomycosis (4), keratosis obturans (10), dermatological: seborrhoeic dermatitis (5), neurodermatitis of EAC (3), allergic: allergic dermatitis (2), otomycosis (4), physiological: furunculosis (3),

otomycosis (3), malignant OE (3), traumatic: neurodermatitis of EAC (4), trauma (11), furunculosis (4), otomycosis (7), microbiological: otomycosis (2), HZO/RHS (4), hereditary/genetic: atopic dermatitis (2), psoriasis (1), others: neurodermatitis of the EAC (2), irritant cause (5), otomycosis (2), OE haemorrhagica (2).

## DISCUSSION

Otitis externa is the generalised condition of skin in EAC characterised by oedema and erythema associated with itchy discomfort with or without otorrhoea. Otitis externa may be acute (<6 weeks) or chronic (>6 weeks) with an intermediate period of acute on chronic (3 weeks-3 months). Acute cases are due to bacterial infection and chronic cases due to allergies and autoimmune disorders.<sup>3</sup> Our study too showed similar values on comparison to other studies based on onset and disease course with progression. 52 patients suffered from acute condition that is 58%.<sup>4,5</sup> While 21 patients suffered from chronic condition that is 24% and lastly 16 patients fall under acute on chronic condition that is 18%. All these features matched studies while did not hold in these studies.<sup>6</sup> Risk factors for acute cases are absence of cerumen, high humidity in canal, retained water in canal, increased temperature, local trauma using various external devices, usage of hearing aids/ear plugs/headphones, swimming while chronic cases have association with skin conditions-psoriasis and dermatitis. People with diabetes, disorders of immune system, seropositive status are at a greater risk. Among 89 patients, 55 patients (62%) had infection as a result of ear picking while rest 34 patients (38%) had other causes of otitis externa, while few studies also shows same findings as mentioned above and few studies do not hold good with the results shown in our study.<sup>7-9</sup>

The list of predisposing factors for OE- It is important that these are kept in mind and hence avoided for better. Anatomical: narrow EAC (hereditary/iatrogenic/exostosis) and obstruction of meatus (keratosis obturans/foreign body/hearing aids/earphones or ear plugs/ headphones). Dermatological: eczema, seborrhoeic dermatitis; allergic: long term use of topical medications prescribed at pharmacy outlets. Physiological: humidity, Immunocompromised (DM, seropositive status). Traumatic: skin laceration (result of swimming), ear probing (with ear buds, safety pins, hairpins, keys, matchstick, toothpick, finger nails, pencil points).<sup>10,11</sup> In our study too, 27 patients that is 30% had traumatic factor as the trigger with typical history of ear picking with easily available and accessible materials especially ear buds. This finding is also matches with studies.<sup>12-14</sup> Microbiological: URI (pseudomonas aeruginosa, staphylococcus aureus, other gram-positive and gram-negative species and also fungal species). Hereditary/genetic factors that are predisposition to ear canal infections. Others: home remedies-topical application of coconut oil, turmeric oil to the ears.

34 patients (38%) had primary symptoms (ear discharge and decreased hearing), 30 patients (34%) had secondary symptoms (otalgia) and 25 patients (28%) had associated symptoms (itching and aural fullness).<sup>15,16</sup>

Furunculosis (localised otitis externa) occurs as a result of ear picking and is more prone in person with diabetes. Secondary to trauma- injury to canal/pinna as a result of road traffic accident, accidental insertion of foreign body/insect, ear picking. It leads to eruption of canal skin causing edema of ear canal with lacerated skin. In both cases, there is severe otalgia with purulent ear discharge. Clinically, pinna and ear canal are tender (tragal sign positive) and on otoscopic examination, tympanic membrane is not visualised as canal is edematous. It is managed conservatively with antibiotics along with analgesics, antihistamines and topical antibiotic ear drops for a week. Sometimes, ear canal pack is placed soaked in Ichthammol glycerol/glycerine magnesium sulphate/steroid containing ointment as they are hygroscopic in nature, to relieve edema of the canal. If conservative line of management fails or furuncle is big, I and D is done and small wick is placed in the cavity with daily dressing till the cavity heals under systemic antibiotic coverage.<sup>17</sup> We encountered 13 cases with furunculosis with history of repeated ear picking present in all of them. Only 4 cases had to undergo I and D as they did not respond to the conservative line of treatment and had neglected initial consultation plus they were diabetic even which matches with studies.<sup>18,19</sup> Most of them followed up, were relieved of their symptoms.

Seborrhoeic dermatitis affects scalp causing scaly patches, skin inflammation and stubborn dandruff. It affects oily areas of the body as ear, face, sides of nose, eyebrows, eyelids and chest which presents with skin flakes and patches of greasy skin. The triggering factors are stress, cold and dry seasons. This condition goes away without treatment or needs repeated treatment to resolve but may even return later. Daily cleansing with a gentle soap and shampoo can help reduce oiliness and dead skin build-up. In our study we came across 5 cases, of which 3 were managed with the treatment mentioned above but the other 2 were referred to dermatologist.<sup>20</sup>

Among 19 patients (21%) had reactive conditions of the ear canal. Among them, 9 patients (47%) had neuro-dermatitis of ear canal due to chronic canal stimulation leading to ever-lasting itching and skin abrasion as in this study.<sup>21</sup> Rest 10 patients (53%) had other reactive conditions.

Irritant dermatitis/allergic dermatitis/atopic dermatitis/psoriasis, most of them have a similar presentation in a way or other. In ear eczema, there is inflamed, itchy rash that develops in the outer as well as inner ear canal. They arise without any triggers, in which case it is called aural eczematoid dermatitis. People prone to seborrhoeic dermatitis or psoriasis are more likely to develop it. Contact with certain irritants can also cause ear eczema.

This type of eczema is called contact dermatitis. Soaps, hair dyes, and metal jewellery can trigger contact dermatitis in and around the ears.<sup>13</sup> This inflammatory skin condition is not contagious. Symptoms are dry, scaly skin around and inside ear with signs of inflammation, pruritus in or around ear canal, clear discharge from ear. They affect area behind ear and its crease where ear attaches to head. People should avoid scratching eczema, as this can lead to inflamed areas of skin that may bleed and make it worse.<sup>2,3</sup> Ear drops are prescribed if eczema is in the canal, antifungal creams, steroids for local application, systemic medications that reduce immune system's response to triggers. We managed all 5 cases with the above mentioned treatment course and this is in sync with the study put up here.<sup>3</sup>

Malignant otitis externa (necrotising otitis externa) is an uncommon form of otitis externa common in old age with poorly controlled diabetics and who are immunocompromised. It begins as infection of external ear canal with extension through Fissures of Santorini, along suture lines, venous and fascial planes leading to bone destruction and cranial neuropathies. Unrecognized and untreated may result in death. It presents as unrelenting, long-standing severe otalgia that interferes with sleep with inflamed and tender canal, purulent otorrhoea, hearing loss. There may be granulations in the floor at bony-cartilaginous junction which is the hallmark.<sup>13,14</sup>

*Pseudomonas aeruginosa* is the most common offending and isolated pathogen. ESR and CRP are significantly raised and HbA1C to check on diabetes which were done in our study too, where in ESR and CRP were drastically raised in 2 cases.<sup>18,19</sup> HRCT temporal bone defines anatomical extent of disease, while MRI assesses initial severity of disease and delineates extent of soft tissue disease and also infers any intracranial complications as in this study. Both HRCT and MRI were done in 2 cases to look for the extent spread.<sup>4</sup> In 1 case, disease had spread up to petrous apex preoperatively and in another case, post 2 months after mastoidectomy, disease had progressed up to clival region.<sup>16,17</sup>

Principle of Rx is to control diabetes, reverse acidosis and improve immune competency wherever possible. Medical management is meticulous glucose control, aural toilet and systemic anti-pseudomonal antibiotics. Aminoglycosides+penicillin/cephalosporins, Quinolones are preferred. Fluoroquinolones (ciprofloxacin) are active against *P. aeruginosa* which is given for atleast 6-8 weeks as in this study the same modality was followed which holds good in most of the studies.<sup>24</sup>

Hyperbaric oxygen is used as adjunct to antimicrobial therapy as it increases partial pressure of oxygen, improves hypoxia and allows greater oxidative killing of bacteria. The surgical line of management (mastoidectomy with or without facial nerve decompression) is removal of sequestra, collection of pus and debridement of necrotised granulations to prevent

further disease progression.<sup>23</sup> We came across 3 cases of MOE, of which one with facial palsy who was treated conservatively with ABx and steroids and managed with mastoidectomy without nerve decompression. While in other 2 cases with no facial nerve of which one case showed recurrence to clival region post mastoidectomy after around 3 months and the other case was resolved with surgical management of which were initially undergone medical line of treatment.<sup>14,15</sup> Unrecognized and untreated, infection continues to smoulder over weeks to months, spreads deeper to involve skull base, petrous apex, clival region leading to skull base osteomyelitis with multiple cranial nerve palsies, meningitis, empyema, sinus thrombosis, brain abscess.

Among 70 patients (79%) were with infective aetiology, 46 patients of 70 that is (66%) had infection due to canal stimulation with external devices whose results holds good with some studies put up here. Rest 24 patients of 70 that is (34%) had other infections of the ear canal.<sup>6-8</sup>

Otomycosis are fungal canal infections ranging from inconsequential to extremely severe ones. Fungi can be saprophytic, when there are no symptoms and fungus simply co-exists in ear canal as harmless parasitic relationship with the host, wherein the only physical finding is presence of fungus. If the fungus begins active reproduction, ear canal fills with dense fungal debris causing pressure and excruciating pain that is unrelenting until fungus is removed from the canal and anti-fungal medications are used. Predisposing factors are-humidity, entry of water during shower, swimming, ear picking. It is usually of 2 varieties: *Aspergillus flavus* (blackish spores) and *Candida albicans* (whitish creamy discharge). It is treated with conservative line of management after proper aural toilet and clearance of mycotic debris. Most antibacterial ear drops also contain a steroid to hasten resolution of canal edema and pain. Along with it, short course of antibiotics, analgesics and antihistamines are given for other associated symptoms.<sup>14,15</sup> These kind of patients are very common at our set up due to the climatic variation, poor hygiene and due to usage of external devices which matches most of the studies mentioned here and holds good in terms of the results.<sup>20,21</sup>

The most commonest causes for otitis externa in our study was found to be otomycosis (22 patients) and furunculosis (13 patients), similar results holds good in certain studies mentioned here while some results do not correlate with few other studies.<sup>23-25</sup>

Herpes zoster oticus/Ramsay Hunt syndrome caused by Varicella zoster virus that starts to replicate first in geniculate ganglion affects facial nerve, inner ear, spiral and vestibular ganglia. They present with painful vesicles with erythematous lesions all over the canal, concha, behind pinna, soft palate and later rupture and forms crusts. It also causes U/L facial nerve paresis that recovers in 1-2 weeks with deep ear pain after 1-2 days.

Patient is treated with antivirals for 7 days, if the patient comes for consultation at the earliest along with the “magic drug” steroid given based on the weight of the patient (1 mg/kg) in tapering dose for 6 days, with topical antibiotic and steroid containing ear drops and eye care.<sup>11,12</sup> In our study, 4 cases presented differently with facial palsy in all of them who presented at different duration of occurrence. They were treated conservatively as mentioned above, of which 1 lost to follow up while the rest 3 were totally resolved of this condition as similar to these study.<sup>22</sup>

OE haemorrhagica, both the varieties have viral etiology. Myringitis bullosa/bullos myringitis-haemorrhagic blebs/vesicles on lateral surface of tympanic membrane and canal skin. Myringitis granulosa- granulations on lateral surface of tympanic membrane and skin of EAC.<sup>10</sup> In both scenarios, there is severe excruciating pain in ear with blood stained discharge. Analgesics, antibiotics to prevent secondary bacterial infections and blebs regress on their own while granulations of post-viral prodromal were locally cauterised. We encountered 2 cases in our study and following conservative line of treatment for symptoms were applied as mentioned above and the granulations were electro-cauterised as similar to these studies.<sup>18</sup>

Neurodermatitis of external canal-inflammation of the ear canal due to frequent ear picking. Initially it will present with features typical of otitis externa. But, patient continues to have itching in the ear canal following the treatment; no matter what as continuous external stimulation over prolonged period of time has led to abrasion of the canal skin permanently. Main modality of treatment is to avoid external stimulation. As temporary measure, ear canal pack is placed soaked in ichthammol glycerol/glycerine magnesium sulphate/steroid containing ointment is kept in the canal for a day or so. After which, antibiotic containing ear drops are to be instilled once the canal pack is removed with antihistamines are given to control the itching for 1-2 weeks.<sup>15</sup> 9 cases in our study, pack was placed in the canal for a day with steroid ointment along with a short course of oral steroids and antihistamines were prescribed for 15 days. Patients were counselled to discontinue external stimulation to the canal. As per the studies mentioned here, nowhere oral steroids were used for this condition which defers the mentioned study but rest of the features hold good as treatment modality.<sup>12,17</sup>

Keratosis obturans, dense plug of keratin gets accumulated deep in the bony canal causing occlusion. It occurs as a result of faulty epithelial migration pattern in the canal. It presents with severe otalgia from an aggressive secondary otitis externa along with deafness, tinnitus and ear discharge. There is a pearly white mass of keratin filling the ear canal with thickening and mucosalization of tympanic membrane.<sup>9</sup> Due to pressure absorption of bony canal, there is widening of the canal leading to facial nerve palsy. Treatment includes removal



of epithelial debris by otomicroscopy and debridement of the canal. In our study, we encountered 10 cases of keratosis obturans and none had facial palsy. They underwent repeated aural toilet and later debridement of the canal was done. This correlates with studies as mentioned here.<sup>26</sup>

## CONCLUSION

Otitis externa ranges from meek to multifarious, agonizing to appalling with sole to several causes. It is important to identify the root cause of this condition and treat it at the earliest in order to prevent complications. Now-a-days, merely visiting pharmacy outlets for momentary benefits has led to temporary relief but on a long run has cost permanent, harmful, irreversible effects. Thus, avoidance of habitual and regular usage of cleaning the ear canal is another important dictum to be kept in mind and followed judiciously. And also evasion of most of the actuating factors as mentioned above can resolve the infection at the initial, early and treatable stage rather making it prolong to final, later and incurable stages hence leading to detrimental changes for life.

*Funding: No funding sources*

*Conflict of interest: None declared*

*Ethical approval: The study was approved by the Institutional Ethics Committee*

## REFERENCES

1. Sander R. Otitis externa: a practical guide to treatment and prevention. *Am Fam Physician*. 2001;63(5):927-36.
2. McKean SA, Hussain SSM. Otitis externa. *Clinical Otolaryngol*. 2007;32(6):457-9.
3. Hui CPS. Acute Otitis Externa. *Paediatr Child Health*. 2013;18(2):96-8.
4. Manolidis S, Friedman R, Hannley M. Comparative efficacy of aminoglycoside versus fluoroquinolone topical antibiotic drops. *Otolaryngol Head Neck Surg*. 2004;130(3):83-8.
5. Bhattacharyya N, Kepnes LJ. Initial impact of the acute otitis externa clinical practice guideline on clinical care. *Otolaryngol Head Neck Surg*. 2011;145(3):414-7.
6. Osguthorpe JD, Nielsen DR. Otitis externa: Review and clinical update. *Am Fam Physician*. 2006;74(9):1510-6.
7. Alter SJ, Vidwan NK, Sobande PO, Omoloja A, Bennett JS. Common childhood bacterial infections. *Curr Probl Pediatr Adolesc Health Care*. 2011;41(10):256-83.
8. Roland PS, Belcher BP, Bettis R, Makabale RL, Conroy PJ, Wall GM, et al. A single topical agent is clinically equivalent to the combination of topical and oral antibiotic treatment for otitis externa. *Am J Otolaryngol*. 2008;29(4):255-61.
9. Rubin GJ, Branstetter BFT, Yu VL. The changing face of malignant external otitis: clinical, radiological, and anatomic correlations. *Lancet Infect Dis*. 2004;4(1):34-9.
10. Martinez DP, Willis CM, Capper JW. External auditory canal pH in chronic otitis externa. *Clin Otolaryngol Allied Sci*. 2003;28(4):320-4.
11. Usatine RP, Riojas M. Diagnosis and management of contact dermatitis. *Am Fam Physician*. 2010;82(3):249-55.
12. van Hasselt P, Gudde H. Randomized controlled trial on the treatment of otitis externa with 1% silver nitrate gel. *J Laryngol Otol*. 2004;118(2):93-6.
13. Schapowal A. Contact dermatitis to antibiotic ear drops is due to neomycin but not to ciprofloxacin. *Allergy*. 2001;56(68):148.
14. Hillen U, Geier J, Goos M. Contact allergies in patients with eczema of the external ear canal: results of the Information Network of Dermatological Clinics and the German Contact Allergy Group. *Hautarzt*. 2000;51(4):239-43.
15. van Balen FA, Smit WM, Zuithoff NP, et al. Clinical efficacy of 3 common treatment in acute otitis externa in primary care: Randomised controlled trial. *BMJ*. 2003;327(7425):1201-5.
16. Rosenfeld RM, Singer M, Wasserman JM, Stinnett SS. Systematic review of topical antimicrobial therapy for acute otitis externa. *Otolaryngol Head Neck Surg*. 2006;134(4S):24-48.
17. England RJ, Homer JJ, Jasser P, et al. Accuracy of patient self-medication with topical eardrops. *J Laryngol Otol*. 2000;114(1):24-5.
18. Davis MD. Unusual patterns in contact dermatitis: medicaments. *Dermatol Clin*. 2009;27(3):289-97.
19. Tsikoudas A, Jasser P, England RJ. Are topical antibiotics necessary in the management of otitis externa? *Clin Otolaryngol Allied Sci*. 2002;27(4):260-2.
20. Nussinovitch M, Rimón A, Volovitz B, Raveh E, Prais D, Amir J. Cotton-tip applicators as a leading cause of otitis externa. *Int J Pediatr Otorhinolaryngol*. 2004;68(4):433-5.
21. Schaefer P, Baugh RF. Acute otitis externa: an update. *Am Fam Physician*. 2012;86(11):1055-61.
22. Gore J. Otitis externa. *J Am Acad Pas*. 2018;31(2):47-48.
23. Wipperman J. Otitis externa. Primary care: clinics in office practice. 2014;41(1):1-9.
24. Rosenfield RM, Schwartz SR, Cannon CR, Roland PS, Simon GR, Kumar KA, et al. Clinical practice guideline: acute otitis externa. *Otolaryngol Head Neck Surg*. 2014;150(1):1-24.
25. Hajioff D, Macketh S. Otitis externa. *BMJ Clin Evid*. 2004(12):755-63.
26. Devesa MP, Willis CM, Capper JW. External auditory canal pH in chronic otitis externa. *Clin Otolaryngol Allied Sci*. 2003;28(4):320-4.

**Cite this article as:** Ballal V, Basavannaiah S. Swimmer's ear: how does ear canal pave its way from 'sensitivity to septicity'? *Int J Otorhinolaryngol Head Neck Surg* 2019;5:1324-9.