

Original Research Article

Widening techniques for stomal stenosis: Y-V advancement vs. two circular incisions technique

Shrinath D. Kamath P., Elizabeth Cherian*, Vadish S. Bhat

Department of Otorhinolaryngology, K S Hegde Medical Academy, Derlakatte, Mangalore, India

Received: 04 September 2016

Accepted: 21 September 2016

***Correspondence:**

Dr. Elizabeth Cherian,

E-mail: necelizabeth@yahoo.com

Copyright: © the author(s), publisher and licensee Medip Academy. This is an open-access article distributed under the terms of the Creative Commons Attribution Non-Commercial License, which permits unrestricted non-commercial use, distribution, and reproduction in any medium, provided the original work is properly cited.

ABSTRACT

Background: Tracheostomal stenosis following total laryngectomy for carcinoma of larynx is a challenging condition for an otolaryngologist, especially when the patient requires post-operative radiotherapy. Critical narrowing of the stoma needs surgical widening. Though there are few surgical techniques described for the same, re-stenosis has been observed in many. We conducted a comparative study of two widening techniques: Y-V advancement and two circular incisions technique.

Methods: A prospective study was conducted, to assess the outcome of 2 surgical techniques: Y-V advancement and two circular incisions technique in patients with tracheostomal stenosis following total laryngectomy. Initially three patients were subjected to Y-V advancement technique for stomal dilatation. But all three patients presented with re-stenosis in a mean period of 8 months and were then subjected to stomal widening by the double circular incisions technique. The next five patients who presented with stomal stenosis underwent widening by two circular incisions technique. All 8 patients were followed up for one year postoperatively.

Results: Among the 8 patients, 3 patients who presented initially underwent stomal widening by the Y-V advancement technique. All 3 patients presented with re-stenosis in a mean period of 8 months post-operatively. Stomal widening using the two circular incisions technique was adopted for these three patients and another 5 patients who presented with stomal stenosis. All 8 patients were found to be maintaining an adequate stoma on one year post-operative follow up.

Conclusions: In our experience, stomal widening by the two circular incisions technique has found to be effective in maintaining an adequate stoma with no features of re-stenosis on a one year postoperative follow up. However a larger study is desirable to conclusion of the same.

Keywords: Stomal stenosis, Y-V advancement, Two circular incisions technique

INTRODUCTION

Stomal stenosis after laryngectomy is a distressing problem. The reported incidence ranges from 4 to 34%.¹ Various contributing factors for stomal stenosis such as female sex, infection, postoperative fistula, improper mucocutaneous approximation, excessive scar tissue, and excessive fat around the stoma, defective or absent tracheal rings, recurrent tumour and failure to wear a stoma button have been identified.²

Various surgical techniques have been described for stomal widening. The simplest technique is to excise the scar tissue all around and suture the refreshed edges together. Other techniques include advancement flaps, Y-V advancement, Z plasty and interposition flaps. The results of various techniques are variable, but excision of majority of scar tissue is essential and breaking of circular scar with interposition flap gives good result.³ In this study we compare postoperative results of stomal widening by Y-V advancement and two circular incisions

technique in 8 patients over a period of three years from 2013 to 2015.

METHODS

A prospective study was conducted at the department of otorhinolaryngology, Justice K S Hegde charitable hospital, Mangalore, to assess the outcome of 2 surgical techniques: Y-V advancement and two circular incisions technique in patients with tracheostomal stenosis following total laryngectomy. Initially three patients were subjected to Y-V advancement technique for stomal dilatation. But all three patients presented with re-stenosis in a mean period of 8 months and were then subjected to stomal widening by the circular incisions technique. The next five patients who presented with stomal stenosis underwent widening by two circular incisions technique after obtaining informed consent. Informed consent was obtained from all individual participants included in the study. All 8 patients were followed up for one year postoperatively.

Y-V advancement technique

A Y incision is made at 3 o'clock and 9 o'clock positions of the stoma. The subsequent flap is advanced into the stoma. Closure is done Y to V, in one or two layers.⁴

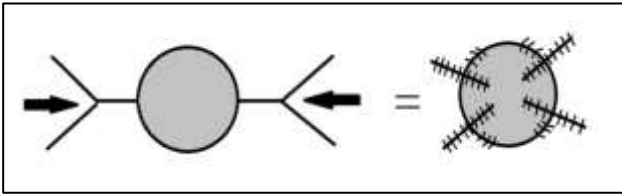


Figure 1: Line diagram of Y-V advancement flap technique.

Two circular incisions technique

Two circular incisions are made around the tracheal opening. The outer one is made incising skin outside the scar tissue and the inner one incising healthy tracheal mucosa. The tissue between the two incisions is removed and discarded, since it consists of scar tissue. Four radial incisions about 5 cm long are made at 10, 2, 4 and 8 o'clock positions. The skin is undermined as far as possible creating four flaps. These flaps are sutured to the tracheal mucosa in two layers-one with 3-0 vicryl and the other with 4-0 ethilon or prolene.⁴

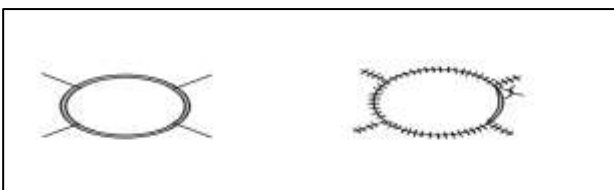


Figure 2: Line diagram of two circular incisions technique.

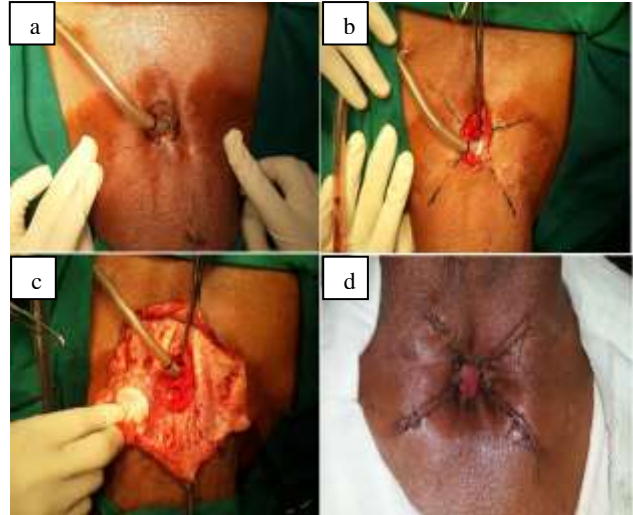


Figure 3: Two circular incisions technique.

a) Circular incision placed around the scar tissue around stenosed stoma with endotracheal tube *insitu* b) Four radial incisions of 5 cms length placed at 2, 4, 8 and 10 o'clock positions c) Four Flaps are elevated d) Flaps are sutured to the trachea in two layers.

RESULTS

In this study, we have compared the results of two different techniques for stomal widening- Y-V advancement technique and two circular incisions technique. Eight patients with stomal stenosis post total laryngectomy were included in the study.

Table 1: Etiology for stomal stenosis.

Etiology	Number
Wound infection	2
Pharyngocutaneous fistula	2
Post radiotherapy	4

In most of the patients, the cause of stomal stenosis was post radiotherapy scarring. Initial three patients underwent stomal widening by Y-V flap technique. But all three patients presented with re-stenosis in a mean period of 8 months. In these patients, stomal widening was performed by circular incision technique. And this technique proved to be effective for them on a one year postoperative follow up.

Table 2: Distribution of patients with re-stenosis.

Technique	Total number	Restenosis
Y-V advancement	3	3
Two circular incisions	5	0

Later five patients underwent stomal widening by circular incision technique. These patients were followed up

monthly for one year postoperatively. It was observed that, following the circular incision technique patients had better post-operative results with an adequate stoma. The size of the stoma was maintained with no further stenosis in one year postoperative follow up.

DISCUSSION

Total laryngectomy for laryngeal or hypo pharyngeal malignancies leaves the person with a permanent stoma. An adequate stoma should be large enough not to require permanent stent, allow adequate clearance of secretion and provide enough space to clean tracheoesophageal prosthesis. Failure to meet these criteria is defined as stomal stenosis.⁵

Montgomery classified tracheostomal stenosis according to the shape of the stoma. He described three type of stenosis: vertical slit which is due to compression from the sternal end of the sternocleidomastoid muscle, concentric which occurs due to scar contraction and inferior shelf type due to redundant skin folds. The most common among these is the concentric type.³ Morphologically, tracheostomal stenosis is described as prevalently concentric or inferior diaphragm-like. The “vertical-fissure” type has more complications, since they are often accompanied by tracheomalacia with a sabre sheath conformation. In our study all 8 patients presented with concentric type of tracheostomal stenosis.

The common etiological factors for stomal stenosis are postoperative infection, post-operative fistula formation and post-operative radiotherapy.⁵ In our study among the 8 patients, 4 had undergone post operative radiotherapy which lead to stomal stenosis. Two patients had post-operative infection and two had post-operative fistula formation causing stomal stenosis.

Stenosis leads to a laminar flow becoming turbulent causing an increase in speed and resistance of air transit, leading to mucosal dehydration and the accumulation of crust. This in turn causes severe super infection-related tracheal inflammation, known as crust-like tracheitis, causing haemoptysis and dyspnoea. An ample tracheostoma is, on the other hand, an essential condition in the application, functionality and maintenance of voice prostheses, which must be easily accessible for cleaning and replacement purposes. The cause of tracheostomal stenosis is chondro-perichondritis of the uppermost tracheal rings as a result of bacterial inflammation, pressure necrosis or preoperative radiation treatment, followed by cicatricial constriction.⁶

Various surgical techniques have been described to create the primary stoma during laryngectomy to avoid stenosis later which include straight transaction of trachea, bevelling the trachea, plastic or flap construction technique.^{7,8} There is no specific evidence in the literature to indicate which method is superior.

The most common cause is inadequate tracheostomal preparation at the time of total laryngectomy. The precautions to be taken include: 1) Avoid excess of peristomal skin 2) the most lateral stitches are applied so that skin traction lateralises the posterior side of the cartilaginous ring 3) while suturing, the skin is well in excess of the tracheal section margin 4) the suture thread has a sufficiently wide diameter to avoid cutting the tracheal ring under traction 5) early removal of the tracheostomy tube to avoid micro trauma and local inflammation.^{3,9}

Treatment modalities ranging from repeated dilatations to various revision surgeries have been described for this condition. Repeated dilatation and stenting is not useful in long term as it has problems like bleeding and excoriation, retained secretions and inability to use TEP. The stomaplasty techniques include the advancement flap and splaying of trachea described by Trivedi et al, the Petal technique described by Lucioni et al, and the double reversing Z plasty with inferiorly widening stomaplasty described by Kim et al.^{1,6,10}

In our study the post-operative outcome of stomal widening by two techniques – Y-V advancement and two circular incisions technique were compared. Among the 8 patients, 3 patients who presented initially underwent stomal widening by the Y-V advancement technique. All 3 patients presented with re-stenosis in a mean period of 8 months post-operatively. Stomal widening using the two circular incisions technique was adopted for these three patients and another 5 patients who presented with stomal stenosis. All 8 patients were found to be maintaining an adequate stoma on one year post-operative follow up.

In the two circular incisions technique the contraction lines of the flaps tend to pull the tracheal mucosa upward and outwards, thus preventing the formation of further stenosis. There is a circumferential traction around the stoma, from the outer skin surface to the tracheal mucosa.

The probable reason for failure of the Y-V advancement technique for stomal widening would be due to the absence of this circumferential traction by the contraction lines by the four flaps around the stoma.

On reviewing the literature we could not find any similar studies done in the past comparing the results of Y-V advancement technique with that of the two circular incisions technique for stomal widening.

CONCLUSION

In our experience, stomal widening by the two circular incisions technique has found to be effective in maintaining an adequate stoma with no features of re-stenosis on a one year postoperative follow up. However a larger study is desirable to conclusion of the same.

ACKNOWLEDGEMENTS

We acknowledge the constant support of Dr. Satheesh Kumar Bhandary, Dean, K S Hegde Medical Academy, Dr. Rajeswari A, Head of the Department of Otorhinolaryngology, K S Hegde Medical Academy, Dr. Kishore Chandra Shetty- Unit Chief, Department of Otorhinolaryngology, K S Hegde Medical academy, whose guidance was of great value to us.

Funding: No funding sources

Conflict of interest: None declared

Ethical approval: Not required

REFERENCES

1. Trivedi NP, Patel D, Thankappan K, Iyer S, Kuriakose MA. Stomoplasty-anterior advancement flap and lateral splaying of trachea, a simple and effective technique. J Postgrad Med. 2008;54(1):21-4.
2. Wax MK, Touma BJ, Ramadan HH. Tracheostoma stenosis after laryngectomy: Incidence and disposing factors. Otolaryngol Head Neck Surg. 1995;113:242-7.
3. Montgomery W. Stenosis of tracheostoma. Arch Otolaryngol. 1962;75:76-8.
4. Watkinson JC, Gaze MN, Wilson JA. Tumours of the Larynx. In: Stell and Maran's Head and Neck surgery. Butterworth and Heinemann. 4th edition. UK: Oxford; 2000: 269.
5. Capper R, Bradley PJ. Etiology and management of tracheostomal stenosis. Curr Op in Otolaryngol Head Neck Surg. 2002;10:123-8.
6. Lucioni M, Rizzotto G, Pazziaia T, Serafini I. Plastic tracheostomal-widening procedure: the "petal" technique. Acta otorhinolaryngolital. 2003;23:291-6.
7. Griffith GR, Luce EA. Tracheal stomal stenosis after laryngectomy. Plast Reconstr Surg. 1982;70:694-8.
8. Lowey A, Laker HI. Tracheal stoma problems. Arch otolaryngol. 1968;87:477-83.
9. Viantis AC, Marres HA, Van den Hoogen FJ. A surgical technique to prevent tracheostomal stenosis after laryngectomy. Laryngoscope. 1998;108:134-7.
10. Kim YH, Kim NH, Seong SY. Double reversing Z-plasty with inferiorly widening stomoplasty for the management of tracheostomal stenosis. Auris Nasus Larynx. 2010;37(3):361-4.

Cite this article as: Shrinath DKP, Cherian E, Bhat VS. Widening techniques for stomal stenosis: Y-V advancement vs. two circular incisions technique. Int J Otorhinolaryngol Head Neck Surg 2016;2:263-6.