

Original Research Article

DOI: <http://dx.doi.org/10.18203/issn.2454-5929.ijohns20200146>

A study of complications of chronic suppurative otitis media at tertiary care hospital

Bhagirathsinh D. Parmar*, Sushil Jha, Vikas Sinha, Nirav Chaudhury, Gavendra Dave

Department of Otorhinolaryngology Head and Neck Surgery, Government Medical College, Bhavnagar, Gujarat, India

Received: 31 October 2019

Revised: 03 January 2020

Accepted: 04 January 2020

*Correspondence:

Dr. Bhagirathsinh D. Parmar,
E-mail: drbhagirath89@gmail.com

Copyright: © the author(s), publisher and licensee Medip Academy. This is an open-access article distributed under the terms of the Creative Commons Attribution Non-Commercial License, which permits unrestricted non-commercial use, distribution, and reproduction in any medium, provided the original work is properly cited.

ABSTRACT

Background: Chronic suppurative otitis media (CSOM) is a still common disease in developing country and is found sometimes difficult to treat. Different complications can develop inspite of availability of higher antibiotics. In pre-antibiotic era, complications of acute otitis media and CSOM were very common and lead to high mortality. Inspite of initial decline in the complication of CSOM due to higher antibiotics, the incidences are still on rise. CSOM remains a serious disease, particularly in developing countries and CSOM-related complications are still found life-threatening. The aim and objective was to study various clinical presentations and management of CSOM related complications.

Methods: All patients of chronic suppurative otitis media with intra or extracranial complication who were admitted in Department of Otorhinolaryngology Head and Neck surgery, Sir. T. General Hospital, Government Medical College, Bhavnagar from July 2015 to December 2018 was included in this study. Data of clinical presentation, associated complication, management, and follow-up were analysed.

Results: Out of 250 patients of CSOM admitted during these 3 years in ENT Department, 36 patients presented with CSOM related complications. 15 patients presented with intracranial complications and 21 patients presented with extracranial complications.

Conclusions: Inspite of availability of higher antibiotics, CSOM related complications are still common. In all the patients require higher intravenous antibiotics (which crosses blood brain barrier) followed by mastoid surgeries.

Keywords: CSOM, High resolution computed tomography scan, Acute otitis media

INTRODUCTION

Chronic suppurative otitis media (CSOM) is still common disease in developing country and sometimes difficult to treat. Different complications can develop inspite of availability of higher antibiotics. In pre-antibiotic era, complications of acute otitis media (AOM) and CSOM were very common and lead to high mortality.¹⁻⁵ Inspite of initially decline in the complication of CSOM due to higher antibiotics, the incidences are still on rise.^{6,7} CSOM remains a serious disease, particularly in developing countries and CSOM-related complications are still found life-threatening.⁴⁻¹¹

The complications of CSOM are classified as extracranial or intracranial. Extracranial complications are further classified into intratemporal and extratemporal.^{3,10,12,13} Intratemporal complications includes mastoiditis, mastoid abscess, petrositis, labyrinthitis, facial nerve paralysis and extratemporal complications includes postaural abscess, zygomatic abscess, Bezold's abscess, meatal (Luc's) abscess, Citelli's abscess, parapharyngeal and retropharyngeal abscess. Intracranial complications includes extradural abscess, subdural abscess, brain abscess (temporal lobe and cerebellar), sigmoid and lateral sinus thrombophlebitis, meningitis, and otitic hydrocephalus. The pathways of extracranial and

intracranial complications include progressive retrograde thrombophlebitis of the venules of the adjoining cranial bones, bone erosion by pressure or enzymatic actions, preformed pathways, and haematogenous spread.^{3,6}

Aim and objective

The aim and objective was to analyse various clinical presentations and management of CSOM related complications.

METHODS

All patients of CSOM with intra or extracranial complication who were admitted in the Department of Otorhinolaryngology Head and Neck surgery, Sir T hospital, Bhavnagar, from July 2015 to December 2018 were included in this retrospective analytic study. All patients underwent detail clinical, otoscopic, microscopic examination. Hearing assessment was done by pure tone audiometry in all patients. Along with all routine investigations including X-ray mastoid Schuller's view, high resolution computer tomography (HRCT) temporal bone was done in every patient. Magnetic resonance imaging (MRI) brain was done in every patient of CSOM related intracranial complications.

Inclusion criteria

Patient of any age and sex having history of ear discharge more than 3 months with either (one or more) intracranial or extracranial complications or both and patients giving positive consent to participate in study were included.

Exclusion criteria

Patients giving negative consent to participate in study and pregnant women were excluded.

Broad spectrum intravenous antibiotics were given to all patients for at least 2 to 3 weeks. Patients having post-aural abscess, subperiosteal abscess or other abscess underwent urgent incision and drainage. In patient of cerebellar abscess, temporal lobe abscess, extradural abscess, perisinus abscess, immediate drainage of abscess was done along with mastoid surgery. In case of brain abscess first aspiration was done and after confirmation, abscess drainage was done. Cerebellar abscess was drained through Trautman's triangle by using brain cannula. In case of lateral sinus thrombophlebitis and sigmoid sinus abscess, after aspiration, drainage was done until the fresh blood came. Canal wall up or canal wall down mastoidectomy was done depending upon the extent of disease, types of complications, postero-superior canal wall erosion, or other intra-operative findings.

Statistical analysis

Simple proportions were calculated.

RESULTS

During July 2015 to December 2018, total 36 patients were presented with CSOM related complications. Out of these 36 patients, 22 were male and 14 were female. Youngest patient was of 4 years old while oldest patient was 52 years old. Highest numbers of patients were seen in 11 to 20 years age groups. Out of 36 patients, four patients were having bilateral CSOM, while rest 32 were having unilateral CSOM.

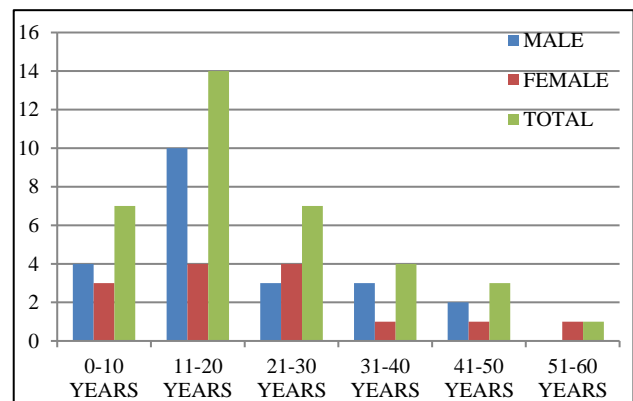


Figure 1: Numbers of male and female complicated CSOM patients in different age groups.

Symptoms of CSOM like ear discharge and decrease hearing were present in most of the patients and in most of the patients these symptoms were present from childhood. Earache was also found in all patients.

Table 1: Symptoms in patients with complications of CSOM (n=36).

Clinical features	Number of patients	%
Vertigo	15	41.66
Nystagmus	11	30.55
Facial weakness	4	11.11
Fever	35	97.22
Headache	27	75
Vomiting	18	50
Postaural swelling	21	58.33
Postaural fistula	1	2.77
Postaural tenderness and other local signs	32	88.88
Meningeal signs	7	19.44
Altered consciousness	12	33.33

In 36 patients, multiple 61 complications were observed, out of which 17 were intracranial (IC) and 44 were extracranial. In one patient only single intracranial complication was seen and in another one patient 2 intracranial complications were seen simultaneously. In 17 patients only single extracranial complication was seen where in 6 patients, more than one extracranial complication was seen. In 12 patients both types of

complications were observed. One patient presented with B/L CSOM with left side mastoiditis and sigmoid sinus thrombophlebitis (after treatment, aspiration & drainage of sigmoid sinus, and left ear canal wall down mastoidectomy) at interval of 5-6 months developed right side mastoiditis and meningitis.

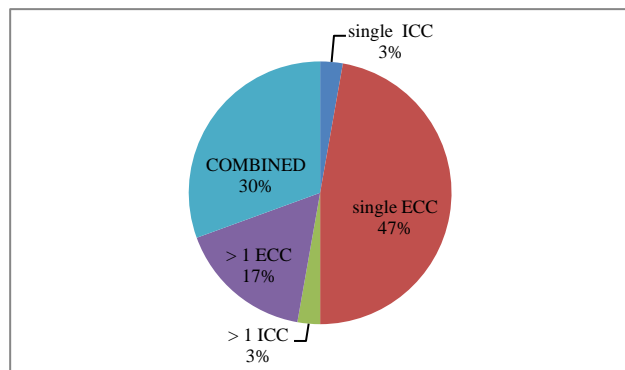


Figure 2: Proportions of complications of CSOM.

Table 2: Intracranial complication of CSOM and its occurrence (n=17).

S. no.	Intracranial complication	Occurrence of complications	%
1	Meningitis	7	41.17
2	Sigmoid/lateral sinus thrombophlebitis	2	11.76
3	Perisinus abscess	1	5.88
4	Cerebellar abscess	3	17.64
5	Temporal lobe abscess	2	11.76
6	Extradural abscess	1	5.88
7	Otic hydrocephalus	1	5.88

In several patients multiple complications observed simultaneously.

Meningitis was most common intracranial complication in this study. Second most common intracranial complication was cerebellar abscess. Single mortality was found in one 6-year-old female patient presented with labyrinthitis and meningitis. Morbidity was found, in terms of profound hearing loss in 6 cases and permanent facial weakness in 2 patients. Postaural abscess was found most common extracranial complications, followed by mastoiditis (second most common) and labyrinthitis (third most common).

In 13 patients severe mixed hearing loss was observed where in 6 patients profound hearing loss was observed and in rest 17 patient's variable degree of conductive hearing loss was found. In all patients X-ray mastoid Schuller's view were done and HRCT (with 0.5-1 mm cuts) were done in most of cases. MRI was done in 13 patients with intracranial complications. MRI venography was done in one patient having sigmoid sinusthrombophlebitis.

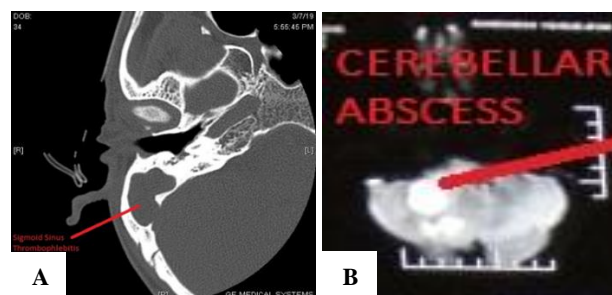


Figure 3: HRCT temporal bone showing (A) sigmoid sinus thrombophlebitis, (B) cerebellar abscess.

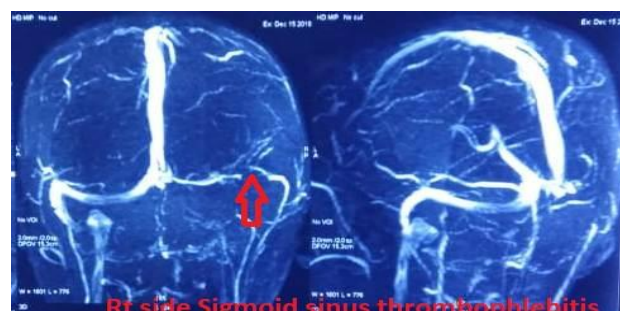

Figure 4: MR-angiography showing right side sigmoid sinus thrombophlebitis.

In 15 cases of complicated CSOM, during intraoperative period granulations/polyps were observe, while in rest 21 cases cholesteatoma was observed. In 15 patients, having different types of subperiosteal abscess, incision and drainage was done first and after 5-7 days of antibiotic course definitive mastoid surgery was done. All three cerebellarabscess were drained through Trautman's triangle. In case of temporal lobe and extradural abscess, after exposing dural plate, abscess drainage was performed. In case of sigmoid sinus thrombophlebitis and perisinus abscess, after needle aspiration and confirmation of abscess, drainage was performed till the fresh blood comes. In all these cases alternate day dressing was done for 7 to 10 days and at least 2 to 3 week of intravenous antibiotic coverage (ceftriaxone and vancomycin) with or without (\pm metronidazole \pm amikacin or gentamycin in early one week) was given.

For definitive management, canal wall down mastoidectomy was done in 15 patients and in rest 20 patients; intact canal wall mastoidectomy (complete cortical mastoidectomy with atticotomy with posterior tympanotomy) was performed. One patient absconded before definitive mastoid surgery.

DISCUSSION

In the study of YorgancÂlar et al and Sharma at al, males were found more commonly affected than female.^{4,5} In this study, male to female ratio was 1.57. In this study, complications were more common in the age group of 11 to 20 years. In other previous study, complications were common in younger and middle age groups.^{7,8,10} The

development of subperiosteal abscess with or without fistula leads to reduction of pressure of pus within the middle ear cleft which in turn reduces the chances of infection spreading intracranially. The mastoid antrum is shallower in younger people. It reaches adult thickness by the age of 16 years. Consequently, we found younger patients frequently develop mastoid abscess and post aural fistula than intracranial complication.⁵

Chronic ear discharge, decrease hearing, fever, headache, post aural swelling are found presenting symptoms in most of the patients. Post aural tenderness and other local ear signs are found as most common clinical features. The most frequent symptoms of patients in this study were otorrhoea, headache, and fever, which were similar to other reports.^{7,16,17} By sensitising physician about these dangerous symptoms and clinical features, we can detect CSOM related complications very early and can reduce the mortality and morbidity of it, because according to various literature one third of adult meningitis are otogenic and 50% of adult brain abscesses are otogenic.

Extracranial complications are found more than intracranial complications.^{7,17} In this study meningitis was the most common intracranial complication and postaural abscess was the most common extracranial complication. According to Osma et al and Samuel et al otitic meningitis is the most common intracranial complication.^{10,18} While according to Osma et al mastoid abscess was the most common extracranial complication.¹⁰ While in the study of Neeta Sharma et al brain abscess was the most common intracranial complication and in the study of Yorgancılar et al, lateral sinus thrombophlebitis was the most common intracranial complication.^{4,5}

HRCT is a proven diagnostic method of choice for evaluating inflammatory diseases of the temporal bone, like CSOM and its complications. MRI is the study of choice for locating otogenic intracranial complications and to access the size of brain abscess. CT may be limited in differentiating soft tissue density in acute infection. In cases of intracranial infection, MRI provide the diagnostic accuracy, with increased sensitivity and specificity.¹⁹ Due to high occurrence of multiple complications, a combination with CT scanning and MRI was recommended in every complicated CSOM patients to exclude other coexisting intracranial complications.²⁰ Magnetic resonance venography is said to be the most definitive method of demonstrating lateral sinus thrombophlebitis. However, it is an invasive procedure and carries a risk of stroke or dislodging the thrombus.²¹ In this study, Magnetic resonance venography was performed only in one patient.

Kangsanarak et al found that 80% of patients had complications associated with a cholesteatoma due to chronic otitis media.² Osma et al reported that 78.5% of patients had a cholesteatoma, while 21.5% had granulation.^{5,10} In 58.33% complicated CSOM patients

intraoperatively cholesteatoma was observed and in rest 41.66% complicated CSOM patients granulations and/ polyp was observed intraoperatively in this study.

According to various studies, the frequency of facial nerve palsy in CSOM ranges from 0.16 to 14.3%.^{10,22-24} In this study, the frequency was 6.55%.

Lateral sinus thrombophlebitis is generally considered the third or fourth most common intracranial complication and is frequently associated with other intracranial and extracranial complications.^{7,8,25} in this study; lateral sinus thrombophlebitis was the third most common intracranial complication. Mostafa et al reported lateral sinus thrombophlebitis as the most common intracranial complication.³ When diagnostic modalities confirm lateral sinus thrombophlebitis, surgery should be immediately scheduled to verify the diagnosis by surgical exploration of the sinus plate. The controversies found intraoperatively are the management of the thrombosed sinus.^{11,13,25} Options range from needle aspiration to complete removal of the thrombosed sinus. Most studies support incision of the lateral sinus and evacuation of the thrombus.^{11,13,15} Seven et al found no difference in outcome between patients who underwent only confirmatory needle aspiration and those in whom the thrombus was removed.⁷ Recent reports have shown that when the surrounding granulation tissue and inflammation are removed through a mastoidectomy, the lateral sinus will recanalize without clot evacuation.^{7,25} However, removal of all infected tissue is mandatory for effective treatment. In this study, in all cases of lateral sinus thrombophlebitis aspiration was done until the fresh blood came out. The routine use of anticoagulation for septic otogenic lateral sinus thrombosis is controversial. Most authors agree that anticoagulants have no place in the management of lateral sinus thrombosis.²⁶⁻²⁸ Anticoagulation has been advocated to prevent extension of the thrombus to distal sinuses.¹⁵ Risks of anticoagulation include releasing septic emboli from clot breakdown, and uncontrollable haemorrhage at the surgical site.¹¹ The indications of anticoagulation treatment in septic otogenic lateral sinus thrombophlebitis include evidence of thrombus progression, neurologic changes, persistent fever, and embolic events.²⁹

In this study, cerebellar abscess was the most common intracranial abscess, followed by temporal lobe, perisinus, and extradural abscess. While according to various studies perisigmoid sinus abscess was the most common intracranial abscess, followed by temporal lobe, epidural, cerebellar, and occipital abscesses.^{4,10,16,25} In this study, perisigmoid sinus abscess was found frequently associated with lateral sinus thrombophlebitis. Occipital and epidural abscess were not observed in this study.

The current mortality rates in patients with intracranial complications of CSOM have dropped to a range of 0–25%.^{4,5,7,16,17} Greenberg et al studied 90 patients who had undergone surgery for complications of CSOM during a

2-year period (1997–1999), and observed no mortalities.²⁶ In this study also decrease in mortality from 16.1% (as reported by Osma et al) to 2.77% was observed. The decrease in mortality rate may be due to early detection, abscess drainage with mastoid surgery within 24 hour of admission in case of intracranial complications, effective antimicrobial coverage and close monitoring and appropriate critical care.¹⁰

CONCLUSION

Life threatening complications of CSOM are still occurring in modern antimicrobial era in developing countries like India because of lack of awareness regarding the symptom like ear discharge and progressive hearing loss. Inappropriate use of antibiotic treatments may cause masked presentations, thereby causing delay in the diagnosis. For early detection and reference, all clinician should be sensitized regarding the dangerous clinical features of complicated CSOM. To reduce mortality of complications of CSOM, early diagnosis of concurrent intracranial complication with HRCT and MRI is required along with proper antibiotic coverage, abscess drainage and mastoid surgery as early as possible.

Funding: No funding sources

Conflict of interest: None declared

Ethical approval: The study was approved by the Institutional Ethics Committee

REFERENCES

- Gandhi B, Agrawal A. Clinical profile of patients with complications following otitis media. Indian J Otolaryngol Head Neck Surg. 2001;53:11-3.
- Midak V, Chavan V, Borade V, et al. Intracranial complications of otitis media: in retrospect. Indian J Otolaryngol Head Neck Surg. 2005;57:130-5.
- Bansal M. Disease of Ear Nose and Throat- Mohan Bansal, 1st edition. Jaypee; 2013: 216-226.
- Yorgancılar M, Yıldırım R, Gün S, Bakır R, Tekin C, Gocmez F, et al. Complications of chronic suppurative otitis media: a retrospective review. Eur Arch Otorhinolaryngol. 2013;270:69–76.
- Neeta S, Ashwin J, Praveer B, Amrith G. Complications of Chronic Suppurative Otitis Media and Their Management: A Single Institution 12 Years Experience. Indian J Otolaryngol Head Neck Surg. 2015;67:353-60.
- Dubey S, Larawin V. Complications of chronic suppurative otitis media and their management. Laryngoscope. 2007;117:264-7.
- Kangsanarak J, Fooanant S, Ruckphaopunt K, Navacharoen N, Teotrakul S. Extracranial and intracranial complications of suppurative otitis media: report of 102 cases. J Laryngol Otol. 1993;107:999-1004.
- Mostafa B, El Fiky M, El Sharnouby M. Complications of suppurative otitis media: still a problem in the 21st century. ORL J Otorhinolaryngol Relat Spec. 2009;71(2):87-92.
- Dubey P, Larawin V, Molumi P. Intracranial spread of chronic middle ear suppuration. Am J Otolaryngol. 2010;31(2):73-7.
- Osma U, Cureoglu S, Hosoglu S. The complications of chronic otitis media: report of 93 cases. J Laryngol Otol. 2000;114:97-100.
- Sennaroglu L, Sozeri B. Otogenic brain abscess: review of 41 cases. Otolaryngol Head Neck Surg. 2000;123:751-5.
- Seven H, Coskun U, Calis B, Sayin I, Turgut S. Intracranial abscesses associated with chronic suppurative otitis media. Eur Arch Otorhinolaryngol. 2005;262(10):847-51.
- Gleeson M. Scott and Browns 7th edition pages. Volume 3. Hodder Arnold Publication; 2008: 3395-3445.
- Singh B, Maharaj J. Radical mastoidectomy: its place in otitic intracranial complications. J Laryngol Otol. 1993;107:1113-8.
- Samuel J, Fernandes M. Lateral sinus thrombosis (review of 45 cases). J Laryngol Otol. 1987;101(12):1227-9.
- Kangsanarak J, Navacharoen N, Fooanant S, Ruckphaopunt K. Intracranial complications of suppurative otitis media: 13 years' experience. Am J Otol. 1995;16(1):104-9.
- Mustafa A, Heta A, Kastrati B, Dreshaj S. Complications of chronic otitis media with cholesteatoma during a 10-year period in Kosovo. Eur Arch Otorhinolaryngol. 2008;265(12):1477-82.
- Samuel J, Fernandes CM, Steinberg JL. Intracranial otogenic complications: a persisting problem. Laryngoscope. 1986; 96(3):272-8.
- Dobben D, Rao B, Mafee F, Kamel A, Mercurio S. Otogenic intracranial inflammations: role of magnetic resonance imaging. Top Magn Reson Imaging. 2000;11(2):76-86.
- Ooi H, Hilton M, Hunter G. Management of lateral sinus thrombosis: update and literature review. J Laryngol Otol. 2003;117(12):932-9.
- Irving M, Jones S, Kendall B, Hall-Craggs A. CT and MR imaging in lateral sinus thrombosis. J Laryngol Otol. 1991;105:693-5.
- Altuntas A, Unal A, Aslan A, Ozcan M, Kurkcuoglu S, Nalca Y. Facial nerve paralysis in chronic suppurative otitis media: ankara numune hospital experience. Auris Nasus Larynx. 1998;25(2):169–72.
- Yetiser S, Tosun F, Kazkayasi M. Facial nerve paralysis due to chronic otitis media. Otol Neurotol. 2002;23(4):580-8.
- Savic L, Djerić R. Facial paralysis in chronic suppurative otitis media. Clin Otolaryngol. 1989;14:515-7.
- Kulali A, Ozatik N, Topcu I. Otogenic intracranial abscesses. Acta Neurochir. 1990;107:140-6.

26. Greenberg S, Manolidis S. High incidence of complications encountered in chronic otitis media surgery in a U.S. metropolitan public hospital. *Otolaryngol Head Neck Surg.* 2001;125:623-7.
27. Jun L, Seong C, Keehyun P, Yun-Hoon C. Managements for lateral sinus thrombosis: does it need the ligation of internal jugular vein or anticoagulants? *Eur Arch Otorhinolaryngol.* 2009;266:51-8.
28. Shah K, Jubelirer F, Fish D, Elden M. A caution regarding the use of low-molecular weight heparin in pediatric otogenic lateral sinus thrombosis. *Int J Pediatr Otorhinolaryngol.* 2007;71(2):347-51.
29. Bradley T, Hashisaki T, Mason C. Otogenic sigmoid sinus thrombosis: what is the role of anticoagulation? *Laryngoscope.* 2002;112:1726-9.

Cite this article as: Parmar BD, Jha S, Sinha V, Chaudhury N, Dave G. A study of complications of chronic suppurative otitis media at tertiary care hospital. *Int J Otorhinolaryngol Head Neck Surg* 2020;6:330-5.