

Case Report

A case report of giant anterior neck lipoma

Shalini Jain*, Sahil Maingi, Ancy S. Sofia, A. K. Rai

Department of Otorhinolaryngology and Head and Neck surgery, Atal Bihari Vajpayee Institute of Medical Sciences, Dr Ram Manohar Lohia Hospital, New Delhi, India

Received: 25 March 2020

Revised: 07 May 2020

Accepted: 08 May 2020

***Correspondence:**

Dr. Shalini Jain,

E-mail: drshalini0201@gmail.com

Copyright: © the author(s), publisher and licensee Medip Academy. This is an open-access article distributed under the terms of the Creative Commons Attribution Non-Commercial License, which permits unrestricted non-commercial use, distribution, and reproduction in any medium, provided the original work is properly cited.

ABSTRACT

Lipoma is a benign mesenchymal tumor with a thirteen percent incidence in head and neck region. Posterior triangle is the most common location while anterior neck lipoma is a rare one. Giant lipomas >10 cm have been reported in different parts of the body but rarely in the anterior neck. Surgical excision remains the treatment of choice. We here report a case of giant anterior neck lipoma in a 50 year old male managed surgically.

Keywords: Lipoma, Giant lipoma, Anterior neck

INTRODUCTION

Lipomas are the most common slow-growing benign mesenchymal neoplasms that can found in any location where fat is normally present. In the head and neck region, where only 13% of lipomas are seen, the posterior neck space is the most common site, but the anterior neck space is a rare location.^{1,2} Here we are reporting a case of lipoma in the anterior neck.

CASE REPORT

A 50 years old male patient presented to ENT OPD with a swelling in the right anterior neck of 2 years duration. It was a slow-growing, painless mass that was not associated with any pain or overlying skin changes. No history of any previous trauma. no history of any difficulty in breathing or swallowing. The patient has taken medical advice only due to cosmetic reasons. On examination, a 11×5 cm, oval shaped, well circumscribed, soft, non-compressible, non-tender mass over the right anterior neck, seen extending vertically from the level of thyroid cartilage to the level of 2nd intercostal space, medially till suprasternal notch and

laterally till midclavicular line, that was not moving with deglutition. The skin over the swelling was normal. There was no accompanying lymphadenopathy.

Imaging studies

On ultrasonography, a homogenous hypoechoic fusiform mass of size 60×42 mm was seen encasing the right sternocleidomastoid muscle. no abnormal vascularity was seen in the mass. the mass has displaced the right carotid vessels posterolaterally.

On fine needle aspiration cytology (FNAC) findings were suggestive of lipoma. On contrast-enhanced magnetic resonance imaging (CE-MRI) of neck, T1W and T2W axial and sagittal images showed a well-defined lobulated hyper intense mass lesion measuring 9.5×4.9 cm in anterior triangle (carotid and muscular triangles) of neck on right side. It showed extension into right occipital and right supraclavicular triangle. Lesion showed hypo intense signals on fat suppressed images. No evidence of restricted diffusion seen. Post contrast scan show no enhancement.

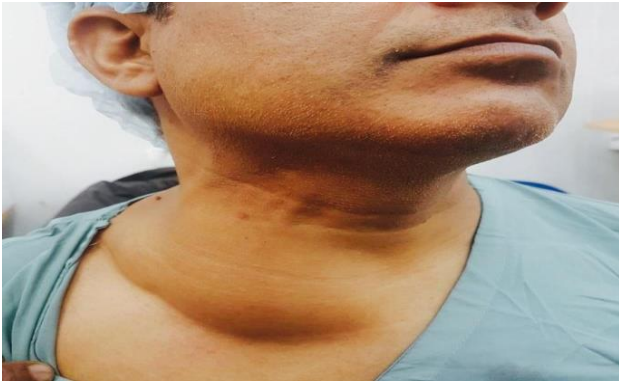

Figure 1: 50 year old male with giant anterior lipoma.

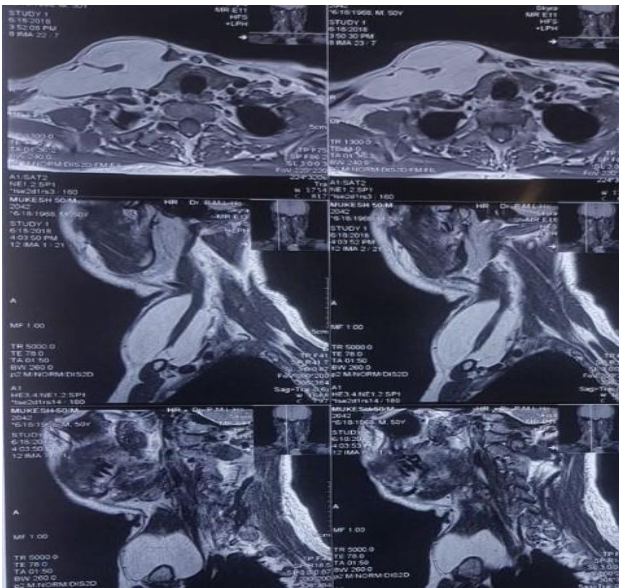


Figure 2: CE-MRI of patient showing hyperintense mass lesion.

Surgery

The patient was worked up for excision under general anaesthesia. The mass was approached via trans cervical incision along the skin crease on the right side. Subplatysmal flap were elevated. Mass was seen encapsulated and by careful dissection, it got freed from underlying sternocleidomastoid muscle and strap muscles. Complete excision with capsule has done.

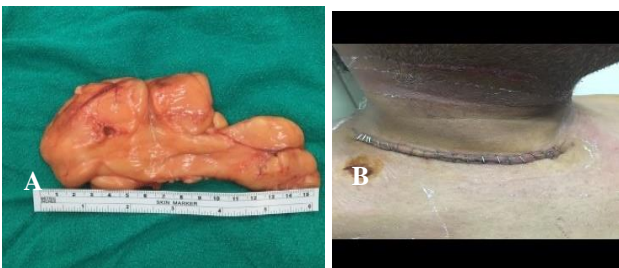


Figure 3 (A and B): Postoperative specimen of mass after surgical excision.

Intraoperative and postoperative was uneventful. Histopathology report was lipoma.

DISCUSSION

Lipomas are benign adipose tumors of mesenchymal origin secondary to hamartomatous proliferation of mature fat cells.³ Of those lipomas that occur in head and neck region, the most common location is posterior neck while that of anterior neck is rare. Based on location, they are classified as subcutaneous type, subfascial type or intramuscular type.⁴ Based on histology, classified into simple lipoma, fibrolipoma, mixolipoma, chondroid lipoma, angiolioma, angiomyolipoma, myelolipoma, spindle cell lipoma, sialolipoma, pleomorphic lipoma and atypical lipoma.⁵

In the head and neck region, men are more often affected than females.⁶ In a series of 25 cases of head and neck lipomas reported by Ahuja et al, 68 per cent were men, correspondingly in the series of Som et al.^{7,8} 52 percent of the cases reported were men. Similarly, here in our case report patient is 50 year old male.

Lipomas usually presents as solitary lesions as in our case report, but multiple site involvement may be seen in alcoholics, diabetes mellitus and syndromes such as Madelung's disease and Kobberling-Dunningan syndromes.⁹

Although the etiology of lipoma is not well known, heredity, obesity, diabetes, trauma, radiation, endocrine disorder, insulin injection and corticosteroid therapy are occasionally implicated as possible etiological features.¹⁰ In our case report cause of this lipoma was found to be idiopathic.

Clinical features depend on the size, location and rate of growth of the lesion. Rarely lipomas reach to a size greater than 10 cm in one dimension, or weighing at least 1000 gm called as a giant lipoma.¹¹ In our case, on examination lipoma of size 11x5 cm was found in the anterior triangle of neck which is very rare both in terms of location and size.

Infiltrating lipoma is a rare variant invading muscles, vessels, nerves or deep soft tissues.¹² When presented as giant lipoma or rapidly progressing infiltrating lipoma, especially in head and neck region should be worked up for malignancy.

Classic benign lipomas often show chromosomal rearrangements of 12q14-15, 6p and 13q.^{9,5} For lipomas, the biggest challenge is differentiating a lipoma from a well differentiated liposarcoma. The absence of vacuoles in the irregularly shaped nuclei and increased size of the cells may be helpful for diagnosis of a well differentiated liposarcoma.¹³

Ultrasonography remains as the initial imaging modality in diagnosis of head and neck lipomas while FNAC or computed tomography or magnetic resonance imaging is indicated for confirmation of diagnosis.

Management is complete surgical excision as we did in our case. Asymptomatic cases can be kept under observation, they need excision if there is diagnostic uncertainty, lack of homogeneity to palpation, large neck masses (more than 10 cm), rapid growth, associated pain, deep seated locations or cosmetic concern.¹⁴ While doing excision, surgeon should be careful to remove the tumor with capsule to prevent recurrence. Liposuction is sometimes preferred especially in certain locations such as the face, as there is less scarring following the procedure but there is higher chance of recurrence, compared with excision.¹⁵

CONCLUSION

Lipomas in the anterior neck are rare, but can present as in our case. Hence lipoma should also be considered as a differential diagnosis of anterior neck swelling.

Funding: No funding sources

Conflict of interest: None declared

Ethical approval: Not required

REFERENCES

1. Barnes L. Tumors and tumor like lesions of the head and neck. In: Barnes L, editor. Surgical Pathology of the Head and Neck. New York: Dekker; 1985.
2. Medina CR, Schneider S, Mitra A, Spears J, Mitra A. Giant submental lipoma: Case report and review of literature. Can J Plast Surg. 2007;15:219-22.
3. Glick M. Burket's Oral Medicine. 12th edition. People's Medical Publishing House; 2015: 732.
4. Marx RE, Diane S. Oral and Maxillofacial Pathology: A Rationale for Diagnosis and Treatment, Second Edition. Quintessence Publishing; 2012.
5. Saenz MAM, Ortiz VJV, Gonzalez MJV, Andrade BG, Arce MAL, Galindo GAS. Dyspnoea and dysphagia associated to hypopharyngeal fibrolipoma: A case report. Ann Med Surg. 2017;16:30-3.
6. Gowri Sankar M, Manu CB, Alexander A. Giant Lipoma Anterior Neck: A case report. Arch Case Rep. 2017;1:6-8.
7. Ahuja AT, King AD, Kew J, King W, Metreweli C. Head and Neck Lipomas: Sonographic Appearance. Am J Neuroradiol. 1998;19:505-8.
8. Som PM, Scherl MP, Rao VM, Biller HF. Rare Presentations of Ordinary Lipomas of the Head and Neck: A Review. Am J Neuroradiol. 1986;7:657-64.
9. Nada G, Omezzine JS, Maher D, Nouha BH, Hssine H. Laryngeal lipoma a rare cause of dysphonia. Pan Afr Med J. 2017;26(9):1-3.
10. Ryu JW, Lee MC, Myong NH. Lipoma of the parotid gland. J Korean Med Sci. 1996;11:522-5.
11. Sanchez MR, Golomb FM, Moy JA, Potozkin JR. Giant lipoma: case report and review of the literature. J Am Acad Dermatol. 1993;28:266-8.
12. Piattelli A, Fioroni M, Rubini C. Intramuscular lipoma of the cheek: a case report. J Oral Maxillofac Surg. 2000;58(7):817-9.
13. Folpe AL, Inwards C. Bone and soft tissue pathology. 1st edition. Elsevier; 2010:97.
14. Bancroft LW, Kransdorf MJ, Peterson J, O'Connor MI. Benign fatty tumors: classification, clinical course, imaging appearance, and treatment. Skeletal Radiol. 2006;35:719-33.
15. Rubenstein R, Roenigk HH, Garden JM, Goldberg NS, Pinski JB. Liposuction for lipomas. J Dermatol Surg Oncol. 1985;11:1070-4.

Cite this article as: Jain S, Maingi S, Sofia AS, Rai AK. A case report of giant anterior neck lipoma. Int J Otorhinolaryngol Head Neck Surg 2020;6:1213-5.