

Short Communication

Simple management of the neck platysma bands: a technique

Clarós Pedro*, Sobolewska Aleksandra, Clarós Andrés

Department of ENT, Clínica Clarós, Barcelona, Spain

Received: 08 July 2020

Revised: 25 August 2020

Accepted: 07 September 2020

*Correspondence:

Clarós Pedro,

E-mail: clinica@clinicaclaros.com

Copyright: © the author(s), publisher and licensee Medip Academy. This is an open-access article distributed under the terms of the Creative Commons Attribution Non-Commercial License, which permits unrestricted non-commercial use, distribution, and reproduction in any medium, provided the original work is properly cited.

ABSTRACT

The aging effect of the neck is characterized by loss of elasticity and contractility of the skin. This aging is manifested clinically by the projection of the platysma bands, the redundancy of the skin, the accumulation of fat in the sub-mental, sub-mandibular regions, and the loss of the cervical-mental angle. Besides of face-lifting, there are other techniques for solving the aesthetic problems of platysma bands. This report aims to present our technique of the simple management of the platysma bands. We report our experience with the correction of platysma bands. The procedure is performed under local anaesthesia. The incision involves the skin and subcutaneous tissue; going from the lateral to the medial edge of the platysma band without cutting the muscle. The dissection of the muscle is continued to the deep side of the bands. This dissection is meticulous to preserve the superficial facial anastomotic plexus and the branch of the transverse cervical nerve afterward the muscle is cut. The technique mainly concerns individuals between the 4th and 6th decades. Women appear to be more concerned about the aesthetic appearance of their neck than men are. This technique is a simple surgical method, and in the majority of the cases, the results are satisfactory. It can be used alone or combined with face lifting. The technique of aesthetic treatment of platysma bands is a simple, effective surgical procedure and in most cases, the results are satisfactory.

Keywords: Platysma bands, Aesthetic, Plastic surgery

INTRODUCTION

The aging of the neck is characterized by the loss of elasticity and contractility of the skin. This aging is clinically manifested by the projection of platysmal bands, the redundancy of the skin, the accumulation of fat in the sub-mental, sub-mandibular regions, and the loss of the cervical-mental angle. The platysmal muscle of the neck, also called platysma is a muscle extended in width, thin and is located under the skin. It has three parts: a medial or anterior part, a central or medial part, and a lateral or posterior part. Platysma bands are one of the first signs of the aging process of the neck that starts at roughly the age of 55 years and increases rapidly throughout the rest of life. The platysmal bands correspond to the surface projection of the anterior edges

of the platysma muscles, which have relaxed over time and are more visible on lean subjects.¹

In addition to the surgical facelift, other techniques can rejuvenate the neck such as platysmoplasty and percutaneous myotomy or lateral displacement of the skin and platysma.^{2,3}

The purpose of our article is to present our surgical technique of the management of platysmal bands in patients who do not accept complete cervicofacial lifting and/or general anaesthesia procedures.

This proposed technique mainly concerns individuals between the 4th and 6th decade. Indeed, the signs of aging of the neck usually appear from half of the fourth decade in both sexes.⁴ Women seem to be more concerned about the aesthetics of the neck than men are.

The anterior platysmal bands of the neck would not be the only result of fibrosis or the rigidity of the platysma muscle but would be the cause of the strong muscular action concentrated on this part of the muscle [4]. The section at the site of the tension of the muscle in a site like in our technique or in several like that of Daher in 2010 would be enough to make disappear the muscular tension which gives the platysma bands.⁴

The treatment of platysma muscle is a constant challenge for surgeons performing facial plastic surgery on the face and neck. Many band correction techniques are effective with satisfactory long-term postoperative outcomes.^{5,6} Most of these techniques include incision and dissection of the skin in the submental cervical region followed by different types of platysmal sutures along the midline, sometimes extending from the chin to the clavicular region.^{4,7,8} The closed platynostomy described by Daher is interesting and gives rather good results. In this case, it requires an experienced surgeon to be able to avoid incidents related to blind work (involvement of the external jugular vein, the mental nerve branch of the facial nerve), a feeling of lumps on the palpation of the neck and the use of a specific instrument that is not always available.⁴

The purpose of this paper was to present a simple, very cost-effective surgical technique that can address platysmal bands.

METHODS

We cross-analyzed patients' files that came to the clinic for complaints of the aging neck. The study was carried out for over 10 years from May 2006 to April 2016. The objective of the study was to analyze our experience with the surgical management of platysma band treatment and to evaluate the aesthetic results of this technique. Complete surgical records of patients treated at our center for medial platysma bands were included. Patient motivation and knowledge of the limitations of the technique were verified in the patient and informed written consent was obtained.

The criteria for non-inclusion were the choice of another technique by the patients, the lateral platysma bands, the association of a facelift, the presence of the psychological disorders in the patient, and disorders of the blood crasis.

The parameters studied were: age, sex, the evolution of the scar, and the degree of satisfaction of the patient with this simple surgical technique. For evaluation, we have used the semantic satisfaction scale, based on "Scaling the semantics of satisfaction" by Lawrence E. Hazelrigg and Melissa A. Hardy.⁹ To the question of whether the patient was satisfied with the result of the surgery, also taking into account the cervical scar, we had four suggested answers which corresponded on the digital scale down to 10: Very satisfied (9 to 10), Rather satisfied

(6 to 8), somewhat dissatisfied (3 to 5), and very dissatisfied (1 to 2).

Preoperative evaluation

Preoperative aesthetic analysis of the face was essential. Front, side, and 3/4 face & neck photos were systematically taken, as well as a biological assessment and a psychological evaluation. Explain clearly and objectively that they are achievable expectations.

Operative technique

The intervention is performed in the operating room. The procedure is performed under local anaesthesia. Our intervention consisted of a demographic pencil marking of the medial platysma band and on the incised area (Figure 1). This was done with the patient sitting and lying, with and without extension of the head to mark the skin projection of the platysma. The patient is placed supine on the operating table in cervical hyperextension.

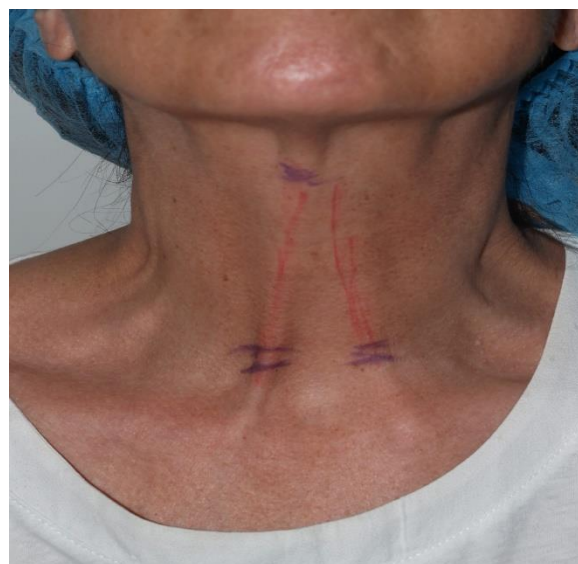

Figure 1: Marking the area to be incised.

Local anesthesia consisted of subcutaneous infiltration at the section area of lidocaine 1% combined with adrenaline using a fine needle to reduce the pain during infiltration. The cutaneous incision was made with a blade n° 15, opposite the platysmal band. This incision interests the skin and subcutaneous tissue; it goes from the lateral edge to the medial edge of the platysma band without cutting the muscle, then the platysmal band is exposed after dissection over the entire width of the medial part. The upper and lower skin flaps are raised on the muscle with two skin hooks. Dissection of the muscle is continued to the deep side of the bands using curved forceps. This dissection is carefully conducted to preserve the superficial facial anastomotic plexus and the branches of the transverse cervical nerve (Figure 2). The muscle section and hemostasis were made with the monopolar electrocautery. The skin closure was intradermal with a

6/0 resorbable thread followed by a non-compressive dressing for 2 to 3 days.

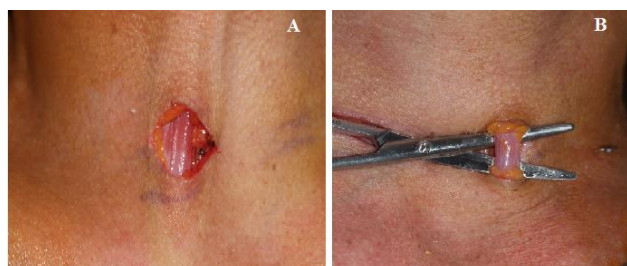


Figure 2: (A) Incision (B) dissection of the platysma.

The average follow-up is 12 months (minimum 10, maximum 24). Immediate operative follow-up may be marked by the presence of ecchymosis at the section site. Immediate (Figure 3) and late postoperative appearance of the scar is satisfactory. The assessment of the patient's satisfaction is made at 1 month, 3 months, 6 months, and a year. The assessment takes into account the scar and the patient's feelings about the initial operation.

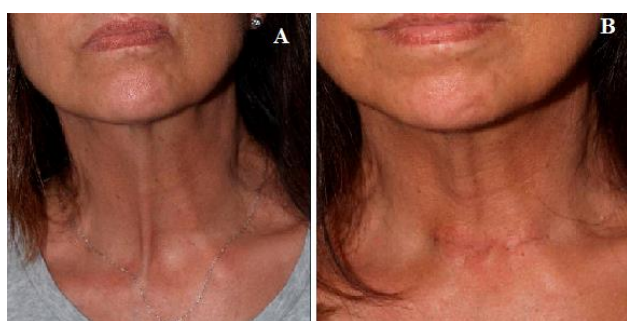

Figure 3: (A) Preoperative aspect (B) immediate postoperative appearance after 15 days.

RESULTS

We counted 150 patients treated by the technique of a single outer section of the platysmal bands of the neck between 2006 and 2016 which met the inclusion criteria. The average age was 57 years old with extremes of 54 and 63 years old. The patients were screened at Day-2 postoperative, Day-7, 1 month, 3 month, and 6 months.

The average follow-up was 7 months (minimum 5 and maximum 12).

The discrete presence of ecchymosis at the section site was present in 80% of the patients at the first control (7th day).

The evaluation of the patient's satisfaction was made at 1 month, 3 months, and after 6 months (Table 1-3). The questionnaire took into account the scar and the patient's feelings about the procedure.

Table 1: It represents the results of 1-month postoperative questionnaires on patient satisfaction.

How do you rate the outcome of the operation on your neck?	Group (150 patients) (%)
Very satisfied (9 to 10)	10
Rather satisfied (6 to 8)	20
Somewhat dissatisfied (3 to 5)	70
Very dissatisfied (1 to 2)	-

Table 2: It represents the results of 3-month postoperative questionnaires on patient satisfaction.

How do you rate the outcome of the operation on your neck?	Group (150 patients) (%)
Very satisfied (9 to 10)	45
Rather satisfied (6 to 8)	35
Somewhat dissatisfied (3 to 5)	20
Very dissatisfied (1 to 2)	-

Table 3: It represents the results of 6-month postoperative questionnaires on patient satisfaction.

How do you rate the outcome of the operation on your neck?	Group (110 patients) (%)
Very satisfied (9 to 10)	85
Rather satisfied (6 to 8)	-
Somewhat dissatisfied (3 to 5)	15
Very dissatisfied (1 to 2)	-

DISCUSSION

Several facelift procedures have been introduced by many surgeons, but no consensus has yet been established regarding a generally superior procedure or clear indications for various surgical methods. In the field of aesthetic surgery, the personal viewpoint of each surgeon still strongly impacts the choice of surgical method.

Our simple platysmal band management technique is characterized by its speed and ease of execution, its low cost even though it is not an argument in cosmetic surgery, a work under visual control that can be performed by any surgeon, and the fact that it is less invasive than the facelift. This simple outer section technique is not a contraindication to a subsequent facelift, later on.

Contraction of the platysma free anterior fibres forms platysma bands. The tension of this muscle is also responsible for creating unwanted horizontal neck wrinkles.¹⁰

From the patient's point of view, the platysmal band is an exceptionally troublesome problem, which gives the appearance of a senile neck. However, it is understandable that some patients are not eager to proceed with neck lift when explained the limited character of this particular pathology.

Methods to correct platysma bands include complex techniques involving undermining skin and muscle, precisely directed traction, and removal of excess tissue.¹¹ In some reports, this particular problem had a tendency to reoccur soon. The study performed by Narasimhan highlighted the importance of midline platysmaplasty. The reappearance of anterior platysmal bands was one of the chiefs complaints in review cases.¹² Finding methods that prolong the outcome remains a challenge for surgical facial rejuvenation.

As presented in previous reports similar techniques using special tools, like platysmotome justified using the minimally invasive procedure for the management of platysmal bands.¹³ We wanted to present in this paper an even more simplified version of a similar surgical idea, which does not need any additional tools, besides those in the standard surgical set.

Many previously presented techniques for correction of platysma muscular bands have proved to be effective, cost-efficient with satisfactory long-term postoperative results.^{5,6}

The results were satisfactory in the majority of our cases. In those who were less satisfied, the platysma bands were not isolated but associated with flaccid skin, which could explain the quality of these results.

The flaccid cervical skin would, therefore, be a partial contraindication to our technique. In these cases, we proposed a complete cervical lift afterward, the patients had accepted in the majority of the cases giving very satisfactory results. We can, therefore, deduce that the simple technique of aesthetic treatment must be reserved for isolated platysmal bands of the young person who sees the aging of his neck begin.

The interesting observational concept proposed by French surgeons was that in patients with unilateral, non-spastic facial paralysis, platysmal bands do not appear on the affected side. The cervical branch of the facial nerve innervates the platysma. Authors suggested that band formation is a consequence of muscle hyperactivity and not skin sagging.¹⁴ Skin laxity comes after the anterior part of the platysma and not the other way around. In the quoted study the authors found that the skin of the neck follows the location and action of the platysma muscle.¹⁴ This concept gives reason for proposed by some authors' techniques of denervation of the anterior part of platysma by Botulinum infection or surgical section of the cervical branch of the facial nerve as alternative techniques.^{13,15}

So techniques that help to release the tensions of the anterior part of platysma like yours are well justified.

The complications have so far been summarized in small bruises and immediate postoperative edema with a disappearance within a few days. The lack of complications is easily understood because when dissection is performed in the right plane, we encounter areas without any anatomical structures of greater importance.

It should always be kept in mind, that outside the area of the procedure, are nearby and worthy of attention: (1) the anterior jugular vein, which is too deep to be reached by this method; (2) the external jugular vein, which although very far to the side of the area of operation, should be marked in advance to avoid the vein in cases that require wider cuts (5 cm); and (3) the marginal branch of the facial nerve, that is more superficial along its distal path, which must be avoided when cuts are made to the bands in the suprahyoid region.⁴

The indication of the complete facelift is very clear but must be careful because of the effects among which: neck edema, scar, postoperative follow-up, discomfort to chewing, and asymmetry of the face and neck. Patients were "very satisfied" in agreement with the initial project in 85% of cases and rather dissatisfied in 15% of cases at 12 months of follow-up.

In addition to these surgical techniques, there are non-surgical and non-invasive techniques such as that using botulinum toxin. The injection of botulinum toxin into the platysma muscle allows, according to some authors, to delay the expiration of the surgical facelift.¹³

Platysma tightening will not always correct platysma bands. The traditional view that all platysma bands were a homogenous problem and simply a consequence of age-associated horizontal platysmal laxity was conceptually flawed and the underlying cause of decades of failed treatment.¹⁶

Years of observations and studies showed that platysma bands comprise a heterogeneous group of distinct problems; they can be recognized as the product of not only horizontal laxity, but also longitudinal platysmal hyperfunction and, as such, resistant to horizontal tightening. Proper management of these issues requires a horizontal platysma section to disrupt longitudinal hyperfunction or other similar treatment.

CONCLUSION

The technique of aesthetic treatment of platysma bands is a simple, effective surgical procedure and in most cases, the results are satisfactory. Platysma belongs to cervical aging. The appearance of the platysmal cord is secondary to an accentuated muscular tension on the medial part of the platysma. The section of the muscle bands concerned

would be an effective solution that could delay the facelift if there is no flaccidity of the associated cervical skin. There is no consensus today on a single technique. This technique can be used alone or combined with a facelift. This technique cannot replace a cervicofacial lift, the long-term results are different.

Funding: No funding sources

Conflict of interest: None declared

Ethical approval: Not required

REFERENCES

1. Santini J, Vailles G. Santini J, Krastinova D. Plastic Surgery of the Face Rehabilitation Embellishment Concepts and Practice. Fren Soc Auto-Rhi-Laryngol Surg Fac Coupl. 1999;131-6.
2. Gonzalez R. Composite platysmaplasty and closed percutaneous platysma myotomy: a simple way to treat deformities of the neck caused by aging. Aesthetic Surg J. 2009 29(5):344-54.
3. Pelle-Ceravolo M, Angelini M, Silvi E. Treatment of anterior neck aging without a submental approach: Lateral skin-platysma displacement, a new and proved technique for platysma band and skin laxity. Plast Reconstr Surg. 2017;139(2):308-21.
4. Daher J.C. Closed platysmotomy: a new procedure for the treatment of platysma bands without skin dissection. Aesthetic Plast Surg. 2011;35:866-77.
5. Nahai F. Reconsidering neck suspension sutures. Aesthetic Surg J. 2004;24:365-7.
6. Fogli A. Skin and platysma muscle anchoring. Aesthetic Plast Surg. 2008;32:531-41.
7. Feldman JJ. Corset platysmoplasty. Plast. Reconstr. Surg.1990;85:333-43.
8. Fournier PF, Carrera C. Closed section of anterior platysma ribbons under local anesthesia. Rev Chir Esthetic. 2005;131:29-40.
9. Hazelrigg LE and Hardy MA "Scaling the semantics of satisfaction," Soc. Indic. Res 2000;49(2)147-180.
10. Trévidic P. and Criollo-Lamilla G. Surgical Denervation of Platysma Bands: A Novel Technique in Rhytidectomy. Plast. Reconstr Surg. 2019;144(5).
11. Hodgkinson D. Total neck rejuvenation using a modified fogli approach and selective resection of anterior platysmal bands. Clin Plast Surg. 2014;41(1):73-80.
12. Narasimhan K, Ramanadham SO Reilly E Rohrich RJ. Secondary neck lift and the importance of midline platysmaplasty: Review of 101 cases. Plast Reconstr Surg. 2016;137(4):667e-75e.
13. Larrouy JC. Lifting médical du cou à la toxine botulique. Ann Dermatol Venerol. 2015;142;6:367-68.
14. Trévidic P, Criollo-Lamilla G. Platysma Bands: Is a Change Needed in the Surgical Paradigm?, Plast Reconstr Surg. 2017;139(1):41-7.
15. de Almeida AR, Romiti A, Carruthers JD. The facial platysma and its underappreciated role in lower face dynamics and contour. Dermatol Surg. 2017;43(8):1042-9.
16. Marten T, Elyassnia D. Neck Lift: Defining Anatomic Problems and Choosing Appropriate Treatment Strategies. Clini Plast Surg. 2018;45(4):455-84.

Cite this article as: Clarós P, Sobolewska A, Clarós A. Simple management of the neck platysma bands: a technique. Int J Otorhinolaryngol Head Neck Surg 2020;7:1927-31.