

Case Series

Intrathyroidal thyroglossal duct cyst: two interesting cases and review of literature

Blessy B. Prabha^{1*}, Vijay Rangachari¹, Vidya B. Bhat²

¹Department of Otorhinolaryngology, ²Department of Histopathology, Manipal Hospitals Whitefield, Bengaluru, Karnataka, India

Received: 31 July 2020

Revised: 05 September 2020

Accepted: 09 September 2020

***Correspondence:**

Dr. Blessy B Prabha,

E-mail: blessybalaji@gmail.com

Copyright: © the author(s), publisher and licensee Medip Academy. This is an open-access article distributed under the terms of the Creative Commons Attribution Non-Commercial License, which permits unrestricted non-commercial

ABSTRACT

The features and presentation of thyroglossal duct cyst as a midline neck swelling are well known. We present two cases of intrathyroidal thyroglossal duct cyst who presented as a classical thyroid nodule. Distinguishing features, clinical work up, management, histopathological findings and literature review are presented. Intra-thyroidal thyroglossal duct cyst masquerading as a thyroid nodule is rare, and should be borne in mind in the differential diagnosis of solitary nodule of thyroid. Preoperative aspiration cytology findings of benign squamous cells should be a pointer towards the presence of intrathyroidal thyroglossal cyst.

Keywords: Intrathyroidal cyst, Thyroglossal duct cyst, Thyroid nodule, Atypical thyroid cyst

INTRODUCTION

Thyroglossal duct cysts are congenital anomalies resulting from persistence of the epithelial tract between the origin at the foramen caecum in the tongue base to the suprasternal region. Variations in its location can be seen anywhere in the tongue, suprahyoid region, infrahyoid region and up to the suprasternal notch, all along the midline of the neck.¹ Among the congenital paediatric neck masses, thyroglossal duct cysts are the most common congenital anomaly with an incidence of more than 75% of midline neck lesions.² Although thyroglossal duct cysts often occur in pediatric patients, around 50% present clinically in the second decade of life or even further later in adult life.³ Presentation of thyroglossal duct cyst as an intrathyroidal lesion is unusual and rare. Very few reports have been published in literature about this entity.

CASE SERIES

Case 1

A 25-year-old lady presented with complaints of lump in the front of neck, to the left of midline of 2 years duration. She noticed that the swelling was insidious in onset and gradually progressing in size to attain the present size. On examination, there was a swelling about 3 cm x 2 cm in size in left lobe of thyroid gland and it moved up with deglutition. The right lobe of thyroid and isthmus was normal. There were no palpable neck nodes. Laboratory investigations revealed euthyroid status. Ultrasonogram of Neck showed a large cyst about 30.1 mm x 24.7 mm in left lobe of thyroid with normal isthmus and right lobe. Fine Needle Aspiration Cytology (FNAC) of the lesion revealed dispersed benign squamous cells, few small sheets of follicular epithelial cells on a background of numerous cyst macrophages,

colloid and neutrophils, being indicative of a thyroglossal duct cyst. She underwent left hemithyroidectomy under general anaesthesia. Intraoperatively, a firm nodule was seen to be occupying the entire left lobe of thyroid (Figure 1). There was no fistulous tract discernible from the thyroid lobe. Gross morphology showed an oval greyish brown nodule and cut surface showed a cystic lesion with surrounding thyroid tissue (Figure 2). Histopathological examination revealed a fibrocollagenous cyst wall lined by granulation tissue, hemosiderin laden macrophages and luminal anucleate squamous cells with congested blood vessels and colloid filled thyroid follicle (Figure 3). The specimen was negative for any malignant changes. The features were consistent with an intrathyroidal thyroglossal duct cyst. She has been symptom free after nine months of follow up.

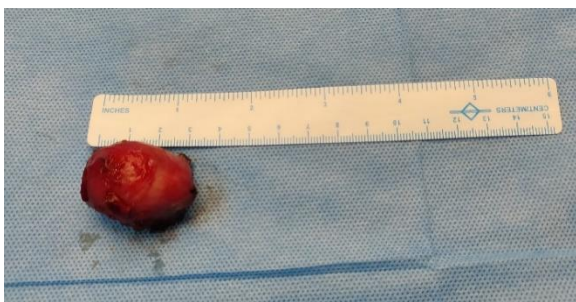

Figure 1 : Nodular thyroglossal cyst specimen.

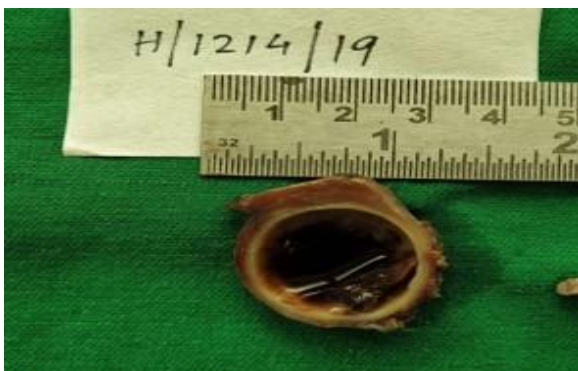

Figure 2: Cystic lesion measuring 3.0 x 2.5 cms with adjacent thyroid tissue.

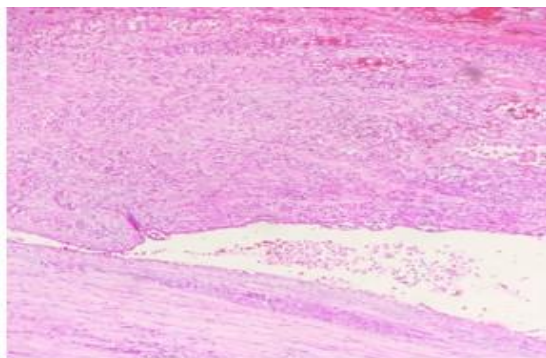


Figure 3: Cyst wall lined by granulation tissue (H&E, 20X).

Case 2

A 41-year-old gentleman presented with complaints of lump in the front of neck, to the left of midline of 2 months duration. He noticed that the swelling appeared recently and progressed to attain the present size. He had no other medical co-morbidities. Clinical examination revealed a soft swelling about 4 cm x3 cm in size in left lobe of thyroid gland and it moved up with deglutition. The right lobe of thyroid and isthmus was normal. No cervical lymphadenopathy was seen. He was euthyroid on laboratory investigations. Ultrasonogram of Neck revealed a large cyst about 49 mm x 43 mm x 35 mm in left lobe of thyroid with normal architecture of the isthmus and right lobe of thyroid. Fine needle aspiration cytology (FNAC) showed paucicellular smears with dispersed mature benign squamous cells and few anucleate squames on a clean background, thereby suggestive of a thyroglossal duct cyst. After counselling, he underwent left hemithyroidectomy under general anaesthesia. Intraoperatively, a cystic ballooned out nodule was seen in the left lobe of thyroid (Figure 4). Gross pathology revealed a cystic lesion at lower pole of left thyroid and cut section showed a unilocular cyst with smooth inner surface (Figure 5). Histopathological examination revealed a fibrocollagenous cyst wall lined partly by cuboidal epithelium with predominantly denuded lining. Cyst wall showed thyroid follicles filled with colloid, thin walled blood vessels and chronic inflammation (Figure 6). There was nothing suggestive of any malignant transformation. Histopathological examination was consistent with an intrathyroidal thyroglossal duct cyst. He has been on follow up of 6 months and is asymptomatic and healed well.

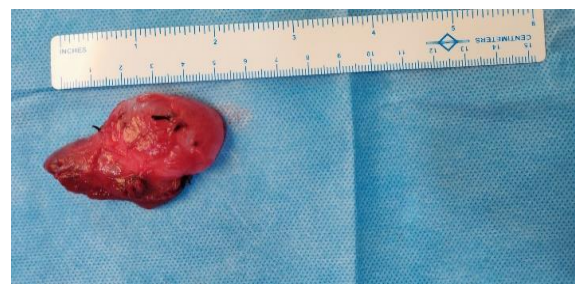


Figure 4: Unilocular thyroglossal cyst specimen.



Figure 5: Cystic lesion at the lower pole of thyroid 4 x 3 cms.

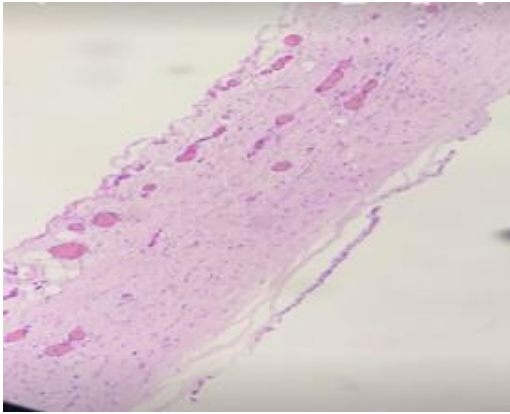


Figure 6: Cyst wall lined by cuboidal epithelium (H&E,20X).

DISCUSSION

Thyroglossal duct cysts develop along the course of the embryonic thyroglossal duct, if any part of the duct persists after the descent of thyroid gland from the foramen caecum to the neck.⁴ A remnant tract leaves a small pouch that passes through the body of the hyoid bone and reaches its final destination anywhere above or below the thyroid gland. Cysts are formed if any material is secreted by the otherwise silent epithelial cells, thereby explaining even late onset of such lesions.⁴ They may often be silent and do not present for several years or decades till the epithelium in the tract becomes secretory in nature and starts producing mucinous material that collects and distends the tract and forms a thyroglossal duct cyst. The usual location of the cyst is midline, starting anywhere from the foramen caecum and usually presenting in infrahyoid or suprahyoid locations.

Location of a thyroglossal duct cyst in an intrathyroidal location is rare. There have been only about five such cases reported in the paediatric population.⁵ Handra-Luca et al have reported that only seven cases of intrathyroidal thyroglossal duct cysts have been reported in adults since 1998, with a predilection for the female gender.⁶ Multiple authors in literature have published isolated single case reports of intrathyroidal thyroglossal duct cysts in adults where all of them presented as a single nodule in the thyroid lobe and were suspected during aspiration cytology and were managed by thyroid lobectomy with isthmusectomy or enucleation of the cyst.^{7,8,9} Saadi et al have reported an intrathyroidal thyroglossal duct cyst which presented as a midline neck mass in the isthmus of the thyroid gland that elevated with both swallowing and protrusion of tongue.¹⁰ After confirming the suspicion of a thyroglossal duct cyst using FNAC, they combined thyroidectomy and Sistrunk procedure. Intraoperatively, the cystic lesion in the thyroid isthmus had a tract extending to the hyoid bone which was also excised simultaneously.

Barber et al have described acute inflammatory manifestations of intrathyroidal thyroglossal duct cyst as

acute pyogenic thyroiditis.¹¹ Hyperthyroidism was detected by them on biochemical evaluation of the patient with a tender thyroid lesion in the neck. The clinical scenario further complicated into a thyroid abscess and was managed by lobectomy. Histopathology was consistent with an intrathyroidal thyroglossal duct cyst.

The possibility of an intrathyroidal thyroglossal duct cyst is to be borne in mind in the differential diagnosis of thyroid nodules. Fine needle aspiration revealing benign squamous cells is usually diagnostic. There is also a possibility of an occult carcinoma arising within the cyst, as reported by North et al.¹²

CONCLUSION

Thyroid nodules should always be worked up with a fine needle aspiration cytology, which can be crucial in detecting a suspicion of thyroid carcinoma, intrathyroidal thyroglossal duct cyst or a colloid nodule. The treatment of choice is surgical excision comprising thyroid lobectomy and isthmusectomy and if any fistulous tract is detected intraoperatively, it also needs simultaneous excision.

Funding: No funding sources

Conflict of interest: None declared

Ethical approval: Not required

REFERENCES

1. Mondin V, Ferlito A, Muzzi E, Silver CE, Fagan JJ, Devaney KO, et al. Thyroglossal duct cyst: personal experience and literature review. *Aur Nasu Lary.* 2008;35(1):11-25.
2. Tunkel DE, Domenech EE. Radioisotope scanning of the thyroid gland prior to thyroglossal duct cyst excision. *Arch Otolaryngol Head Neck Surg.* 1998;124(5):597-9.
3. TürkyiLmaz Z, Sönmez K, Karabulut R, DemirÇoullari B, Sezer C, BaŞaklar AC, et al. Management of thyroglossal duct cysts in children. *Pediatr Int.* 2004; 46(1):77-80.
4. Johnston R, Wei JL, Maddalozzo J. Intra-thyroid thyroglossal duct cyst as a differential diagnosis of thyroid nodule. *Int J Pediatr Otorhinolaryngol.* 2003;67(9):1027-30.
5. Perez-Martinez A, Bento-Bravo L, Martinez-Bermejo MA, Conde-Cortes J, de Miguel-Medina C. An intra-thyroid thyroglossal duct cyst. *Eur J Pediatr Surg.* 2005; 15(06):428-30.
6. Handra-Luca A, Wei S. Intrathyroid cystic thyroglossal duct remnant and ectopic thymus: a fortuitous or development-related association? *Surg Tod.* 2018;48(8):815-8.
7. Choi HJ, Jung JH, Yoo J, Kang SJ, Lee KY, Chun CS et al. Intra-thyroid Thyroglossal Duct Cyst: A Case Report. *Korean J Pathol.* 2007;41(2):132-4.
8. Hatada T, Ichii S, Sagayama K, Ishii H, Sugihara A, Terada N et al. Intrathyroid thyroglossal duct cyst

- simulating a thyroid nodule. *Tumori J.* 2000;86(3):250-2.
9. Kim DH, Kang MJ, Kim JP, Lee JS, Seo JH, Park JJ. A Case of Intrathyroid Thyroglossal Duct Cyst. *Int J Thyroidol* 2018;11(2):167-71.
 10. Saadi R, Goldenberg D. An intrathyroidal thyroglossal duct cyst. *ENT J.* 2015;94(10-11):446-7.
 11. Barber J, Martinez DS, Diaz FP, Stark AP, Livhits MJ. Intrathyroidal thyroglossal duct cyst: A rare cause of thyroiditis in an adult. *AACE Clin Case Rep.* 2018;4(1):e90-3.
 12. North Jr JH, Foley AM, Hamill RL. Intrathyroid cysts of thyroglossal duct origin. *Am Surg.* 1998;64(9):886.

Cite this article as: Prabha BB, Rangachari V, Bhat VB. Intrathyroidal thyroglossal duct cyst: two interesting cases and review of literature. *Int J Otorhinolaryngol Head Neck Surg* 2020;6:1906-9.