

## Original Research Article

# Utility of island bipaddle pectoralis major myocutaneous flap in reconstruction of full thickness lower gingivo-buccal sulcus defects

Ravi P. Deo, Balan Ashok Kumar\*, Sagayaraj A., Azeem Mohiyuddin S. M.

Department of Otorhinolaryngology and head and neck Surgery, Sri Devarj Urs Medical College and Hospital, Kolar Karnataka, India

**Received:** 19 October 2020

**Accepted:** 03 December 2020

### \*Correspondence:

Dr. Balan Ashok Kumar,

E-mail: drbalanashok84@gmail.com

**Copyright:** © the author(s), publisher and licensee Medip Academy. This is an open-access article distributed under the terms of the Creative Commons Attribution Non-Commercial License, which permits unrestricted non-commercial use, distribution, and reproduction in any medium, provided the original work is properly cited.

## ABSTRACT

**Background:** Aims of the study was to evaluate the usefulness of island bipaddle pectoralis major myocutaneous flap in the reconstruction of through and through lateral gingivobuccal sulcus defects.

**Methods:** This was a retrospective study carried out from 2013 - 2019 in the department of otorhinolaryngology and head and surgery at Sri Devaraj Urs Medical College and Hospital. After obtaining institutional ethical committee clearance. Sixty-one patients diagnosed with stage IV a lateral Gingivobuccal squamous cell carcinoma with skin involvement and reconstructed using island bipaddle pectoralis major myocutaneous flap were included in the study.

**Results:** Majority of our patients were females. Nearly 50% of our patients had skin involvement secondary to Level-I nodal metastasis. Nine patients in our study developed complications. Among them seven patients had minor complications and in two patients the flap failed.

**Conclusions:** In resource constraint places where microvascular reconstruction facilities are not available and where replacing bone is not mandatory, island bipaddle pectoralis major myocutaneous flap can be used effectively as single stage reconstruction option for full thickness lower gingivo-buccal sulcus defects.

**Keywords:** Oral cancer, Pectoralis major myocutaneous flap, Reconstruction

## INTRODUCTION

As such India has a high incidence of Head and Neck Cancer accounting for 30% of all cancers. In recent years there's increase in consumption of all forms of tobacco, leading to a higher incidence of head and neck Cancers. Unlike western countries where smoking is common form of tobacco consumption, habit of placing betel/tobacco quid in Gingivobuccal sulcus is common in south and south Asian countries. This has led to a higher incidence of oral cancers in particular the buccal/gingivobuccal sulcus cancers.<sup>1,2</sup>

Most of the patients in this subgroup are advanced at presentation with through and through disease, involving

the overlying skin in variable dimensions. Resection of such cancer's mandates reconstruction of both inner and outer lining. Microvascular flap reconstruction is the well-established method when resources are available. However, in a resource constrained setup such as ours, various loco regional flaps are still in use. All of which are known to cause significant donor site deformity and some of them requiring two stage surgical procedure. A standard Pectoralis major myocutaneous flap (pmmc) although commonly used, is quite bulky and impractical.

Island bipaddle pectoralis major myocutaneous flap is a versatile modification of a standard pectoralis major myocutaneous flap, which provides just enough bulk, incorporating two skin paddles to provide both inner and

outer linings. It can be a practical, alternate option for the microvascular reconstruction. This study aims to evaluate the usefulness of island bipaddlepectoralis major myocutaneous flap in the reconstruction of through and through lateral gingivobuccal sulcus defects.

## METHODS

This retrospective study was carried out from 2013 to 2019 in the department of otorhinolaryngology and head and surgery at Sri Devaraj Urs Medical College and Hospital. After obtaining institutional ethical committee clearance (No.SDUMC/KLR/IEC/28/2020-21).A total numbers of 61 patients were included in our study.

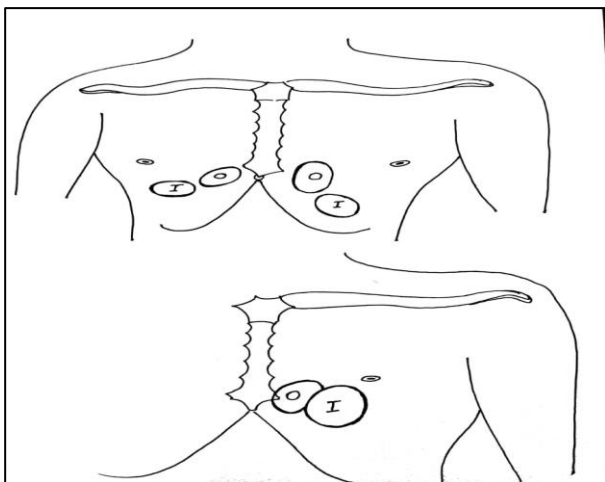
### Inclusion criteria

Patients diagnosed with stage IVa lateral Gingivobuccal squamous cell carcinoma with skin involvement were included in the study.

All patients underwent wide excision of the primary tumor with excision of involved skin with hemimandibulectomy and modified radical neck dissection sacrificing sternocleidomastoid muscle.

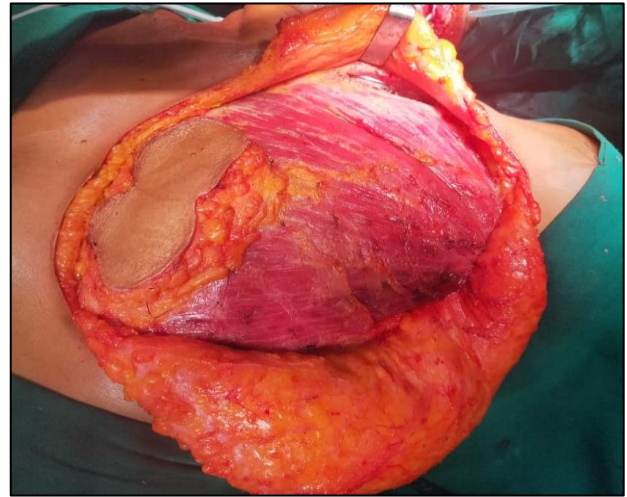
### Methodology

The skin paddles are designed in accordance with the resultant defect after resection of the primary tumor. Since we routinely employ two team approaches working almost simultaneously, the planning is elaborate. The skin paddles are routinely planned on the parasternal region, thus avoiding the bulky region of the breast. This also ensures less distortion of the breast. This region is chosen as it is richly supplied by the vascular anastomotic area of internal thoracic artery and the pectoral branch of thoraco-acromial artery.



**Figure 1: Schematic diagram depicting skin paddle design, (a) for super imposing defects, both transverse and vertical orientation of skin paddles, (b) for non-superimposing defects.**

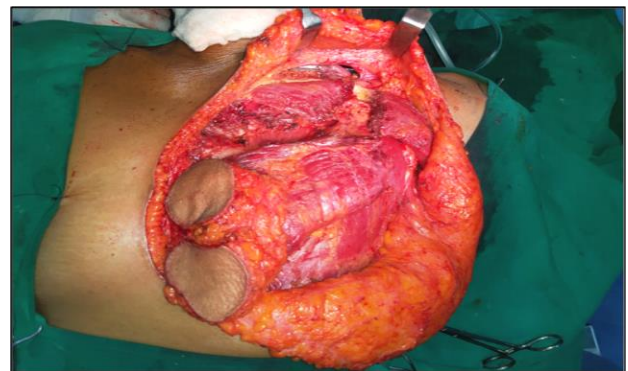
Two distinct designs can be followed for the through and through disease, where in the skin involvement actually superimposes the oral component (Figure 1). A) One skin paddle above the other in a vertical fashion. B) Side by side skin paddles placed horizontally.



**Figure 2: Intraoperative picture after raising skin flap showing isolated skin paddles.**

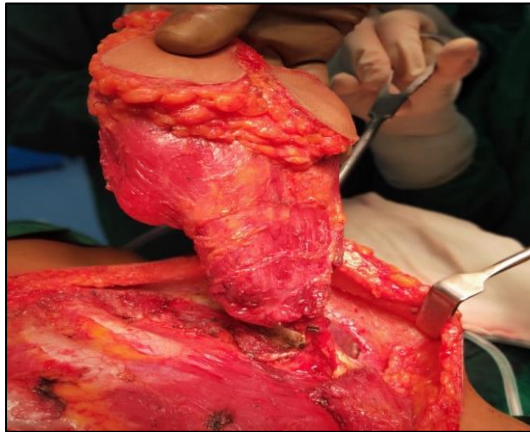However, when it comes to defects, which are not superimposed where the skin over Level-I node is involved, we need to plan the paddle to have enough separation to cover non-superimposing defects. This can be done by creating the second paddle on the cusp of the inner paddle, leaving some gap between the two.

Once the paddles are carefully marked, templates are made using under exposed X-ray films or any plastic sheet. This helps fine tune the skin paddle depending on the length of the muscle during the harvesting. We either use an oblique skin incision corresponding to the lower limb of the deltopectoral flap, starting from the anterior axillary fold and extending to the superior edge of the proposed skin island, or a sub mammary incision, thereby avoiding going through the bulky breast parenchyma.



**Figure 3: Intraoperative picture showing bipaddle PMMC flap based only on sternocostal fibres excluding clavicular fibre.**

Routinely, the superior aspect of the oblique incision is taken and the lateral border of the pectoralis muscle is identified. As the muscle is delineated further, the incision is extended downwards. Once we are sure of the length of the muscle available, we place the template and the skin islands are marked. We then work on the under surface of the muscle. Without much distortion of the skin paddles, the incisions are completed all around the skin paddles (Figure 2). An island of skin between the two paddles can be de-epithelized to facilitate folding, especially for the non-superimposed defects.



**Figure 4: Intraoperative picture showing completed bipaddle PMMC flap based on thin vascular pedicle, which is traced till its origin.**

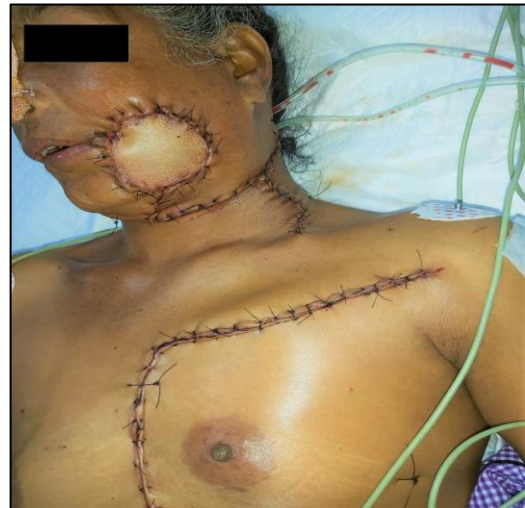Using blunt dissection, the pectoralis major muscle is separated from the chest wall and the pectoralis minor muscle. It is important to stay very close to the chest wall and include the intercostal perforators with the flap. These perforators need to be ligated or cauterized very close to the chest wall as it helps in opening up intramuscular collateral circulation thereby improving vascularity of skin paddles. In the process, the vascular pedicle is now visualized along its course.

The superior skin flap is now elevated till the clavicle. This exposes the groove between the sternal and the clavicular fibres. The groove is now used to separate the sternal and the clavicular flaps. The clavicular fibres at this point are never included in the flap (Figure 3). The humoral attachment of the external fibres are held between the thumb and the index finger and cut using monopolar cautery in coagulation mode. This manoeuvre helps unfold the muscle and expose the main pedicle along its length.

It is our practice to retain the lateral pedicle until we are sure of the status of the medial main pedicle. The medial sternal fibres of the muscle are now cut. Here again the fibres above the vascular arborisation are not included which further reduces the bulk. The clavicular fibres overlying the main pedicle are carefully dissected from the pedicle and cut. The clavicular branches supplying these fibres are cauterized and the pedicle is now traced

till its origin (Figure 4). Extreme care should be taken to safeguard the venous tributaries.

Just before the delivery of the flap to the neck, the lateral pedicle is sacrificed. The wound is thoroughly irrigated and drains are placed in position and the donor site is closed primarily. When the linear design of skin paddle is used, the proximal skin paddle is used for intra-oral closure and the distal paddle is used for external cover. In a transverse/oblique design, the lateral skin paddle is used for intra-oral closure and the medial skin paddle is used for external cover (Figure 5).



**Figure 5: Post-operative picture showing reconstruction done with island bipaddle PMMC flap.**

## RESULTS

**Table 1: Epidemiology, nodal staging, skin involvement, complication.**

Factors	Patients (n=61)
Females	46 patients
Males	15 patients
Common age group	50-70 years
<b>Nodal staging</b>	
N1 Nodes	25 patients
N2a Nodes	15 patients
N2b Nodes	15 patients
<b>Skin Involvement</b>	
Secondary to level -I node	30 patients
Secondary to primary tumor	31 patient
<b>Complication</b>	
<b>Minor complication</b>	
Partial necrosis of external skin paddle	3 patients
Wound dehiscence at donor site	4 patients
<b>Major complication</b>	
Total Flap necrosis	1 patient
External skin paddle Necrosis	1 patient

Among the 61 patients (Table 1), 46 patients were females and 15 patients were males. Majority of our patients were within the age group of 50-70 years of age. Fifty-five patients had presented with nodal metastasis. Twenty-five patients were staged N1, 15 patients were staged N2a and 15 patients were staged N2b. Thirty patients had skin involvement secondary to Level-I nodal metastasis.

Nine patients had complications. Seven patients had developed minor complication and two patients had major complications. Among the 7 patients with minor complication, 3 patients had developed partial necrosis of external skin paddle and 4 patients had wound dehiscence at donor site, they were all managed with wound debridement and secondary suturing. One patient had total flap necrosis another patient had developed necrosis of external skin paddle; they were salvaged with other regional flaps.

## DISCUSSION

Since its inception, pectoralis major myocutaneous flap has been the work horse in Head and Neck reconstruction.<sup>3</sup> Off late, it had fallen into disrepute due to various factors like its bulk, distortion of breast in female patients, restricted rotation and reach.<sup>3</sup> Although, micro vascular free tissue transfer is the ideal reconstruction option following resection of lateral gingivobuccal cancers, it requires expertise and resources, which may not be available in most peripheral centres.

In resource constraint places pectoralis major myocutaneous flap is still being utilized. It has its advantage since it is located adjacent to head and neck region, is quick to execute, requires no change in patient position and last but not least, requires no additional infrastructure or expertise.<sup>4</sup>

We had earlier modified a standard pectoralis major myocutaneous flap to reduce bulk and create an island flap incorporating only the sternocostal muscle fibres based on the pectoral branch. This was based on vascular studies, which clearly showed that the clavicular fibres predominantly receive their blood supply from the acromion, deltoid and clavicular branches of the thoracoacromial trunk, whereas the sternocostal fibres are exclusively supplied by the pectoral branch.<sup>5,6</sup>

Omitting the clavicular fibres not only reduces the bulk, but avoids kinking of the vessel and increases the length and reach of the flap. Studies have shown that once the other branches of the thoracoacromial artery is cauterized or ligated, there is an increase in perfusion in the pectoral branch, thereby increasing the blood supply to the skin paddles.<sup>7</sup>

To increase the vascularity of the skin paddles the skin islands were planned in the parasternal and

inframammary region as this region is richly supplied by the vascular anastomosis of the pectoral branches and the intercostal perforators of the internal thoracic artery. By incorporating two skin paddles we could achieve a single stage primary reconstruction of both inner and outer linings without much distortion or deformity of the donor area.<sup>3</sup> Results from our study were similar to other studies on bipaddle pectoralis major myocutaneous flap with success rate of 96% (Table 2).<sup>8,9</sup> As every patient underwent modified neck dissection, postoperative shoulder dysfunction can be worrisome. We hence advocate vigorous post-operative physiotherapy to reduce their morbidity.

**Table 2: Complication rate in comparison to other study.**

Complication rate	Bhathena et.al. (n=48)	Ahmed et.al (n=47)	Our study (n=61)
<b>Flap necrosis</b>	3 (6%)	01 (2%)	01 (1.6%)
<b>Minor complication</b>	4 (8%)	16 (34%)	08 (13%)

## CONCLUSION

In resource constrained places where microvascular reconstruction facilities are not available and where replacing bone is not mandatory, island bipaddle pectoralis major myocutaneous flap can be used effectively as single stage reconstruction option for full thickness lower gingivo-buccal sulcus defects. As it was observed in our study, with careful planning and sound anatomical background this flap can safely be used even in female patients.

*Funding: No funding sources*

*Conflict of interest: None declared*

*Ethical approval: The study was approved by the Institutional Ethics Committee*

## REFERENCES

1. Sankaranarayanan R, Ramadas K, Amarasinghe H, Subramanian S, Johnson N. Oral cancer: prevention, early detection, and treatment. In: Gelband H, Jha P, Sankaranarayanan R, Horton S, editors. Cancer: Disease Control Priorities. Third Edition. Washington (DC): The International Bank for Reconstruction and Development. The World Bank. 2015:85-100.
2. Kulkarni MR. Head and neck cancer burden in India. Int J Head Neck Surg. 2013;4:29-35.
3. Deo SS, Purkayastha J, Das DK, Kar M, Srinivas G, Asthana S, et al. Reconstruction of complex oral defects using bi-paddle pectoralis major flap-technical modifications and outcome in 54 cancer patients. Indian J Otolaryngol Head Neck Surg. 2003;55:5-9.

4. Sahu PK, Kumar S. Bipaddle pectoralis major myocutaneous flap for single stage reconstruction of oromandibular defects. *Indian J Otolaryngol Head Neck Surg.* 2019;72:44-8.
5. Rikimaru H, Kiyokawa K, Watanabe K, Koga N, Nisshi Y, Sakamoto A. New method of preparing a pectoralis major myocutaneous with a skin paddle that include third intercostals perforating branch of the internal thoracic artery. *Plast Reconstr Surg.* 2009;123:1220-8.
6. Sagayaraj A, Deo RP, Mohiyuddin SA, Modayil GO. Island pectoralis major myocutaneous flap: an Indian perspective. *Indian J Otolaryngol Head Neck Surg.* 2012;64:270-4.
7. Freeman J, Walker E, Wilson J, Shaw H. The vascular anatomy of the pectorals major myocutaneous flap. *Br J Plast Surg.* 1981;34:3-10.
8. Bhatena HM, Kavrana NM. The folded, bipaddled pectoralis major composite flap in oral reconstruction. *Br J Plast Surg.* 1989;42:441-6.
9. Ahmad QG, Navadgi S, Agarwal R, Kanhere H, Shetty KP, Prasad R. Bipaddle pectoralis major myocutaneous flap in reconstructing full thickness defects of cheek: a review of 47 cases. *J Plast Reconstr Aesthet Surg.* 2006;59:166-73.

**Cite this article as:** Deo RP, Kumar BA, Sagayaraj A, Mohiyuddin ASM. Utility of island bipaddle pectoralis major myocutaneous flap in reconstruction of full thickness lower gingivo-buccal sulcus defects. *Int J Otorhinolaryngol Head Neck Surg* 2021;7:56-60.