

Case Report

Cochlear implantation in osteogenesis imperfecta in India: a case report

Rajesh Kumar¹, Ashvanee K. Chaudhary^{1*}, Sunil Kumar¹, Vishwambhar Singh¹,
Ashutosh A. Abinashi², Subhadeep Das³

¹Department of Otorhinolaryngology, Institute of Medical Sciences, Banaras Hindu University, Varanasi, U.P., India

²Department of Otorhinolaryngology, Government Medical College, Azamgarh, U.P., India

³Department of Otorhinolaryngology, North Eastern Indira Gandhi Regional Institute of Health and Medical Sciences, Shillong, Meghalaya, India

Received: 27 November 2020

Accepted: 07 January 2021

*Correspondence:

Dr. Ashvanee K. Chaudhary,

E-mail: drashvaneebhu21@gmail.com

Copyright: © the author(s), publisher and licensee Medip Academy. This is an open-access article distributed under the terms of the Creative Commons Attribution Non-Commercial License, which permits unrestricted non-commercial use, distribution, and reproduction in any medium, provided the original work is properly cited.

ABSTRACT

A 25 years old male patient with osteogenesis imperfecta presented with bilateral profound hearing loss, not benefitted with hearing aid. Cochlear implantation of 12 channel intracochlear implant was done successfully, intracochlear insertion of the 12 electrodes resulted in hearing improvement of 80 dB at frequency 250 Hz to 4 KHz. The patient complained of facial twitching on first visit after switching on speech processor device, reducing the current level at the electrode 6 abolished the non-acoustic nerve excitation with preservation of acoustic performances. Osteogenesis imperfecta patient may involve a risk for non-acoustic nerve activation in cochlear implant patients possibly resulting from a decrease impedance to current spread, it happens because of abnormal bone tissue. Non acoustic nerve activation can be overcome by modification in mapping.

Keywords: Cochlear implant, Osteogenesis imperfecta, Facial twitching, COLIA-1 and COLIA-2, Type-1 collagen, Rheumatic heart disease

INTRODUCTION

Osteogenesis imperfecta is a rare genetic disorder of connective tissue caused by defective collagen type-I formation.¹⁻⁴ Mutation on chromosome 7 or chromosome 17 results in decreased synthesis or structurally abnormal type-I collagen or both.¹⁻⁴ The disease is characterised by abnormal bone fragility, osteopenia, blue color of the sclera, defective dentition, hearing loss and ligamentous laxity. The triad of fragile bone, blue sclera and progressive hearing impairment was first described by Van derHoeve, and De-Kleyn in 1917 and was thus named van derHoeve-de Kleyn syndrome.²

Type-I collagen is the most plentiful protein in the body. Osteogenesis imperfecta is the result of a mutation involving several genes responsible for the intracellular

processing of type-1 collagen. Ninety Five percent of Osteogenesis imperfecta cases are due to dominantly transmitted mutation involving COLIA-1 or COLIA-2 genes which are responsible for the synthesis of the proalpha-1 and proalpha-2 polypeptide chain involved in the formation of type-1 collagen triplehelix.^{3,4}

No correlation has been established to differentiate between mutations affecting the COLIA1 and COLIA2 genes and hearing loss in osteogenesis imperfect.^{3,4} Blue sclerae result from altered light reflection in the presence of abnormal scleral collagen.³ Tendon and ligament involvement leads to hyperextensible joints. Type-1 collagen in vascular structure leads to mitral and aortic valve involvement as well as aortic dilatation in some cases. Finally disordered type-1 collagen in ear involve each of the auditory structure, both hard and soft tissue

leading to early onset of hearing loss. There is ground of belief that both deficient and abnormal ossification was found in the bony walls of middle ear and ossicles.⁴ Micro fracture were present in the otic capsule, in the anterior process handle of malleus and at the crura of the stapes. The cochlear and vestibular end organ seems to be normal. It is of interest that the osteogenesis imperfecta auditory system did not show changes consistent with otosclerosis.⁴

Therefore we postulated that the patients with Osteogenesis imperfecta, where hearing loss decreases predominantly from middle ear manifestation of the disease could be benefitted from intracochlear implantation. However the abnormal bone structure of this patient may evolve difficulties during both, surgery and the post-operative period. This paper draws attention to a special problem of non-acoustic nerve stimulation related to unique pathological change in temporal bone that occurs in relation to osteogenesis imperfecta.

CASE REPORT

A 25 years old male came to our department with a history of progressive hearing loss in both ears from past 18 years. He had a history of established osteogenesis imperfecta. He had been completely hearing impaired for last 9 years, at the time of visit to the department he could no longer be benefitted from digital hearing aids on either side.

Otoscopy showed bilateral normal tympanic membrane. The functions of both facial nerve were normal on clinical examination. Pure tone audiometry revealed no response to air conduction stimuli up to 120 dB. No response was obtained in bone conduction at any frequency to 80 dB on either side. Auditory brainstem response using click stimulus was without effect on either side. Tympanogram was normal in both ear. The stapedius reflex could not be elicited. Systolic murmur was heard on auscultation. Computed tomography scanning of the temporal bone was performed that showed abnormal borderline areas of lucency surrounding the cochlea on both sides. There was a loss of definition of the cochlear architure with demineralization and annular osteolysis in the surrounding otic capsule on either ear (Figure 1A and B). 2-D echocardiography revealed rheumatic heart disease with severe mitral regurgitation with mild pulmonary regurgitation with mild atrial hypertension, left ventricular systolic function was preserved.

The right ear appeared to be the less abnormal with a normal cochlear lumen. After discussion with the patient about the possible gain to be expected from cochlear implantation, a decision was taken to offer him for cochlear implant. This patient was also suffering from cardiac problem and lower limb deformity so cardiology consultation was taken prior to implant surgery. In surgical procedure, cochlear implantation with VARIA method was done. A separate cochleostomy was created antero-inferior to the round window niche and the scala tympani was entered. The electrode array was passed into the

cochlea without difficulty. All the 12 electrodes were successfully positioned inside the cochlea. An intra-operative intra field telemetry was measured which was within normal limits (Figure 2).

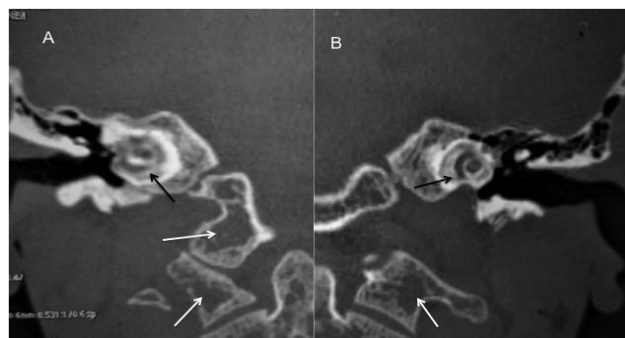


Figure 1: Coronal reconstructed computed tomography (CT) images of (A) right and (B) left temporal bones show ill-defined areas of reduced density in the pericochlear bony otic capsule (black arrows). Note is also made of marked diffuse osteoporotic changes (white arrows).

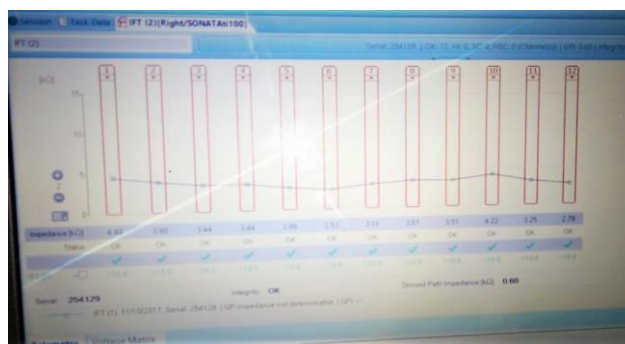

Figure 2: Impedance across the electrode array intraoperatively.

Auto auditory response threshold has been done. Three layered closure was done. The patient was shifted to intensive care unit (ICU) postoperatively in view of the cardiac complications and was discharged after a week. After three weeks of surgery, electrode threshold check was done which showed low impedance and auto auditory response threshold. The speech processor was switched on. The patient revisited after one month for mapping and complained of facial twitching, during mapping session. Reducing the current level at the electrode 6 abolished the non-acoustic nerve excitation with preservation of acoustic performances. Postoperatively regular mapping is done on follow-up, Electrode response and growth function of all 12 electrode is seen normally. Electrode response and growth function of electrode 1, 6 and 11 are shown (Figure 3-5).

A hearing improvement of 80 dB at frequency 250 Hz to 4 KHz was observed after cochlear implantation, aiding to significant improvement in the quality of life of the patient.

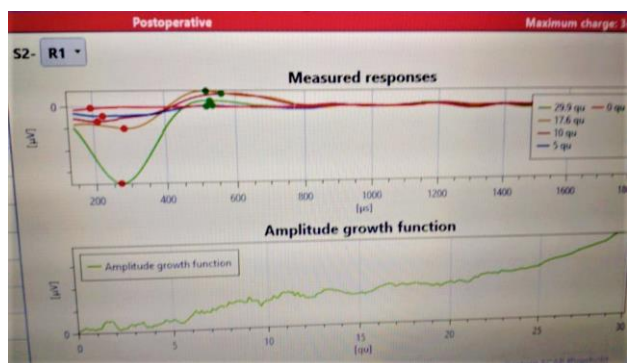


Figure 3: Response of electrode array 1 and amplitude growth function postoperatively.

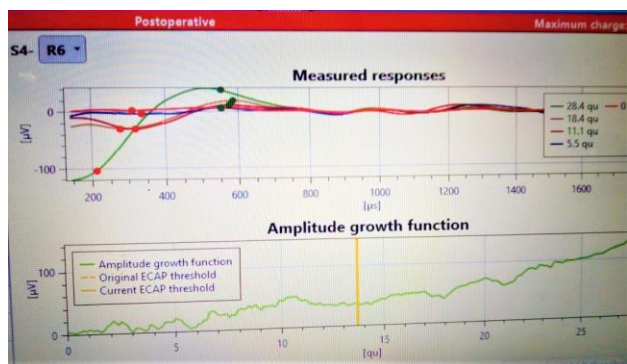


Figure 4: Response of electrode array 6 and amplitude growth function postoperatively.

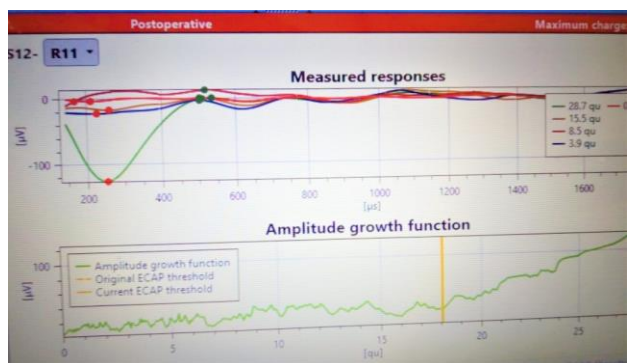


Figure 5: Response of electrode array 11 and amplitude growth function postoperatively.

DISCUSSION

This case report is the best example to show that hearing loss associated with osteogenesis imperfecta can be successfully treated with intra-cochlear implantation of a multichannel device. In spite of successful intracochlear positioning of the each electrode, the electrode array implanted equipment, switching on of the external device revealed facial twitching upon activation of electrode 6 only whereas in another study it was noted upon activation of electrode number 9-13, so the site of leaking current can be vary as per site of osteoporosis around cochlea.¹ Vetter et al have mentioned the higher prevalence of aortic root

dilatation, Aortic stenosis (AS), Atrial septal defect (ASD) and tetralogy of fallot (TOF) in children with osteogenesis imperfecta (OI) whereas we found in our study that patient had rheumatic heart disease with severe mitral regurgitation with mild pulmonary regurgitation with mild atrial hypertension.^{5,6} Ashournia et al have also reported valvulopathies and aortic dilatation among the patient with OI.⁷ Folkestad et al have advocated the collagenopathy to be in root of pathogenesis of CVD in patients with OI.⁸

Cochlear implantation has been shown to be a safe surgical procedure with few immediate or long-term complications.² Unwanted effects include electrode stimulation of the facial nerve. In absence of temporal bone abnormalities, the adverse effects result mostly from current spread from electrode which lie outside the cochlea and if so, can be corrected by reducing the current level of those electrodes.³ However, facial nerve stimulation sometimes results from current spread from electrode positioned within the cochlea. Otosclerosis and temporal bone fracture are the two well-known conditions which are most likely to be associated with this phenomenon.⁴ A similar association between osteogenesis imperfecta and an increased likelihood for non-acoustic nerve excitation by intracochlear stimulation is not surprising, since temporal bone abnormalities in osteogenesis imperfecta and otosclerosis are very similar.^{9,10} However, Ross et al postulated that osteoclorosis and OI in spite of difference in etiology might sometimes coexist, otosclerosis being part OI.¹¹ Thus osteogenesis imperfecta is a situation similar to that previously described in cochlear implant patients with temporal bone fracture or otosclerosis coexists. The introcochlear stimulate may be fraught with danger to the cochlear implant recipients. Regarding the mechanism it is possible that a decrease in electrical resistance in the diseased temporal bone due to either line may give rise to an electric field in that proximity of the facial nerve that results in a sufficient degree of depolarization of certain fibres. No direct evidence has been provided for altered impedance of the otosclerotic/OI temporal bone compared to normal bone.

Whatsoever the precise mechanism is, the present result clearly show that osteogenesis imperfecta similar to otosclerosis, even a special clinical condition when electrical field stimulation of the cochlea stimulate the facial nerve. Some electrical field stimulation activates all types of neurons in a corresponding electrical field with minimum or no selectivity for the neural element it was intended originally to excite.

CONCLUSION

We hypothesize that temporal bone abnormalities in this disease are possible, the underlying factors in the spread of the electrical field outside the cochlea. It is also observed that selection of implant is important to reduce the facial nerve activation, only those implant may be selected where there is no reference electrode outside the implant and number of electrode should be less. It is also observed that

mapping manoeuvres can overcome this adverse effect. After modification in mapping complain of facial twitching resolved, since then no further complain and with regular follow up patient doing well, perform daily routine work normally and hearing status of patient is also good.

Funding: No funding sources

Conflict of interest: None declared

Ethical approval: Not required

REFERENCES

1. Szilvassy J, Jori J, Czigner J, Toth Z, Szilvassy F, Kiss JG. Cochlear implantation in osteogenesis imperfect. *Acta Otorhinolaryngologica*. 1998;52:253-6.
2. Alkadhi H, Rissmann D, Kollias SS. Osteogenesis Imperfecta of the Temporal Bone: CT and MR imaging in Van der Hoeve-de Kleyn Syndrome. *Am J Neuroradiol*. 2004;25:1106-9.
3. Hermie I, Horvath M, Cauter SV. Temporal Bone Imaging features in Osteogenesis imperfecta. *J Belgian Soc Radiol*. 2017;101(1);27.
4. Pillion JP, Vernick D, Shapiro J. Hearing loss in osteogenesis imperfecta: Characteristics and treatment considerations. *Gen Res Int*. 2011;983942.
5. Vetter U, Maierhofer B, Muller M. Osteogenesis imperfecta in childhood: cardiac and renal manifestations *Eur J Pediatr*. 1989;149(3):184-7.
6. Karamifar H, Ilkhanipoor H, Ajami G, Karamizadeh Z, Amirhakimi G, Shakiba M. Cardiovascular Involvement in Children with Osteogenesis Imperfecta. *Iranian J Pediatr*. 2013;23(5):513-8.
7. Ashournia HJ, Johansen FT, Folkestad L, Diederichsen ACP, Brixen K. Heart disease in patients with osteogenesis imperfecta - A systematic review. *Int J Cardiol*. 2015;196:149-57.
8. Folkestad L, Haldd JD, Gramc J, Langdahl BL, Hermann AP, Diederichsen ACP, Abrahamsen B, Brixen K. Cardiovascular disease in patients with osteogenesis imperfecta — a nationwide, register-based cohort study. *Int J Cardiol*. 2016;225:250-7.
9. British bone society. Hearing Loss and Osteogenesis Imperfecta. Available at: www.brittlebone.org. Accessed on: 09 August 2020.
10. Neto AM, Santos T, Santos AM. Osteogenesis imperfecta: Clinical features and imaging overview. *Eur Soc Radiol*. 2009;78854628.
11. Ross U, Laszig R, Bornemann H, Ulrich C. Osteogenesis imperfecta: clinical symptomatic and update findings in computed tomography and tympanic-cochlear scintigraphy. *Acta Otolaryngol*. 1993;113:620-4.

Cite this article as: Kumar R, Chaudhary AK, Kumar S, Singh V, Abinashi AA, Das S. Cochlear implantation in osteogenesis imperfecta in India - a case report. *Int J Otorhinolaryngol Head Neck Surg* 2021;7:392-5.