

## Original Research Article

# A clinical study and management of ulceromembranous lesions of oral cavity

Stanley John, Muniraju M., Sreekala S. S.\*, Julie P. R.

Department of Otorhinolaryngology, Dr. B. R. Ambedkar Medical College and Hospital, Bangalore, Karnataka, India

**Received:** 09 December 2021

**Revised:** 12 January 2022

**Accepted:** 13 January 2022

**\*Correspondence:**

Dr. Sreekala S. S.,

E-mail: [sreekala190@gmail.com](mailto:sreekala190@gmail.com)

**Copyright:** © the author(s), publisher and licensee Medip Academy. This is an open-access article distributed under the terms of the Creative Commons Attribution Non-Commercial License, which permits unrestricted non-commercial use, distribution, and reproduction in any medium, provided the original work is properly cited.

### ABSTRACT

**Background:** This study was done at Dr BR Ambedkar Medical College, Bangalore between November 2019 to May 2021 in the department of ENT to know the clinical profile of patients presenting with ulceromembranous lesions in oral cavity.

**Methods:** A longitudinal prospective study done with the patients coming to Department of Otorhinolaryngology and also the patient referred from other departments of Dr. B R. Ambedkar medical college from November 2019 to May 2021. After obtaining informed written consent, all patients with ulceromembranous lesions in the oral cavity, a detailed medical history recorded, thorough ENT clinical assessment as well as a systemic check up done. Swab was obtained and sent for Gram's stain, culture, and sensitivity, KOH mount. In suspected malignant ulceroproliferative lesions, biopsies were collected from the edges of the lesions. All information was entered into a custom-made case preforma. Patients were treated symptomatically with appropriate antibacterials and antifungal medicines. Patients with malignant ulcers who gave consent were taken for surgery.

**Results:** There were 100 cases of ulceromembranous lesions in oral cavity. Females (60%) were most commonly affected. Majority of patients had tobacco chewing as a risk factor for the development of malignant lesions. 15% of study subjects had aphthous ulcer as the most common cause of ulceromembranous lesion. Malignant lesions constitute 27% of total cases.

**Conclusions:** Malignant etiology is most commonly associated with ulceromembranous lesions in oral cavity in our study.

**Keywords:** Ulceromembranous lesions, Oral cavity, Carcinoma tongue, Smoking, Hard palate, Tobacco

### INTRODUCTION

Ulceration of the oral mucosa is common, resulting in painful "aphthae," a term of ancient origins that refers to ulceration of any mucosal surface. Oral mucous membranes are fragile, specialised membranes that are prone to erosion. Painful ulceration results from full thickness epithelial erosion into the lamina propria. Once an ulcer has formed, it is continually irritated by saliva and microflora, and the acute inflammatory stage may be followed by a pattern of chronic inflammation. Although

there are many diverse causes, oral ulcers frequently demonstrate similarity both clinically and histologically.

Oral ulcers are one of the predominant complaints of patients visiting ENT OPD. The global prevalence in the general population is predicted to range from 4.9 percent to 64.7 percent. Aphthous ulcers can afflict up to a quarter of the world's population. Oral mucosal lesions affect 4.1 percent of people in South India.<sup>1</sup> A loss or break in the integrity of the surface epithelium or mucous membrane that continues into the lamina propria is

known as an ulcer. If the duration of the ulcer is less than 3 weeks, it is called as a short term ulcer, and if the duration is more than or equal to 3 weeks, it is categorised as a long term ulcer. The membranous lesion is an inflammatory disease in which cells on the surface of the mucous membrane are killed, exudate is laid down on the surface, and the entire necrotic layer is connected to the underlying tissue by fibrosis to produce a false membrane, as seen in diphtheria.<sup>2</sup>

Ultero-membranous lesions in the oral cavity have a variety of origins, and the disorder can affect mucous membranes in other sections of the body as well as the oral cavity and oropharynx. They could be a symptom of a local or systemic illness. Because of the wide range of symptoms that a single sickness might have, as well as the fact that a variety of diseases can come, the practitioner must approach the diagnosis and treatment in an orderly fashion.<sup>3</sup> The morbidity associated with ultero-membranous lesions in the oral cavity and oropharynx, as well as their impact on an individual's overall health, is significant. An explanation is required when the colour, texture, or consistency of the oral mucosa changes. In certain cases, the history and clinical presentation are sufficient for a definite diagnosis, although biopsy with submission of lesional tissue for histologic assessment is frequently required. A clinician's ability to recognise common oral mucosal lesions and recognise whether a specific lesion requires histologic diagnosis is crucial.<sup>2</sup>

## **METHODS**

Our study was conducted among patients attending the department of otorhinolaryngology and also patients referred from other departments of DR. B. R. Ambedkar Medical College and Hospital, Kadugondanahalli, Bangalore. The study was conducted for a period of one and half years from November 2019 to May 2021.

### ***Study design***

The study was a prospective study.

### ***Inclusion criteria***

Patients presenting with ulceromembranous lesions in the oral cavity, aged 18-65 years.

### ***Exclusion criteria***

Pregnant women, lactating women, patients below 18 years, patients above 65 years.

### ***Sample size***

Patients of ultero-membranous lesions in the oral cavity by purposive sampling, sample size of 100 was arrived at conducting the study.

### ***Sampling method***

The sampling method was purposive sampling.

### ***Ethical approval***

The study was done with the patients coming to Department of ENT and also the patients referred from other departments of Dr. B. R. Ambedkar medical college and hospital, Bangalore, was approved by Institutional ethical committee. Informed written consent was taken from the study subjects after explaining to them the plan and intention of the study in the language best known to them.

### ***Statistical methods and tools***

Statistical methods and tools included context chart, analysis table.

A specially designed proforma was used to collect data on each individual subject. Patients aged 18 to 65 visiting ENT outpatient department with ultero-membranous lesion in oral cavity were evaluated. Detailed history regarding tobacco usage such as tobacco chewing, betel nut/quid chewing, smoking and nasal snuff was elicited. History regarding alcohol, drug intake was taken. Patients who have received radiotherapy for head and neck malignancies were also included in the study. History of any drug intake prior to appearance of ulcers was also noted. History was elicited regarding any joint pain or joint stiffness. History of any skin disorders in the family was also noted. Burning sensation in mouth, throat discomfort, dysphagia, odynophagia, foreign body sensation in throat, halitosis, cough, retrosternal burning pain, swelling in the neck, fever, generalised malaise, and weight loss were among the symptoms reported by these patients. Patients exhibiting systemic symptoms that could indicate an autoimmune illness were referred to the department of medicine for additional investigation. Patients with genital ulcers were referred to the Dermatology department for additional assessment.

## **RESULTS**

A total of 22147 patients attended ENT OPD during the study period from November 2019 to May 2021, of which there were 100 patients with ultero-membranous lesions in oral cavity which accounted to 0.45%. Among these patients 40 were males (40%) and 60 were females (60%).

The highest number of ultero-membranous lesions was seen in female patients in the age group 36-45 years (17%) and male patients in the age group 46-55 years (17%). Least age of the patient encountered in this study was 22 years male. Highest age of the patient in this study was 65 years. Mean age in this study was 47.7 years.

**Table 1: Distribution of cases according to gender.**

Gender	Number
Male	40
Female	60
<b>Total</b>	<b>100</b>

**Table 2: Distribution of cases according to age.**

Age group (yrs)	Male	Female
18-25	2	0
26-35	2	11
36-45	7	17
46-55	17	16
56-65	12	16
<b>Total</b>	<b>40</b>	<b>60</b>

**Table 3: Distribution of risk factors among study subjects.**

Risk factors	Number
Smoking	22
Alcohol	13
Both smoking and alcohol	8
Tobacco chewing	39
Both smoking and tobacco chewing	13
Smoking, alcohol and tobacco chewing	8
Gutka chewing	8
Nasal snuffing habit	2
No addictions	48

**Table 5: Distribution of cases according to various treatment modalities.**

Treatment	Number
Conservative management	68
Radiotherapy	6
Surgery	21
Both surgery and radiotherapy	1

Most common site affected in our study is mucous membrane followed by hard palate and then tongue.

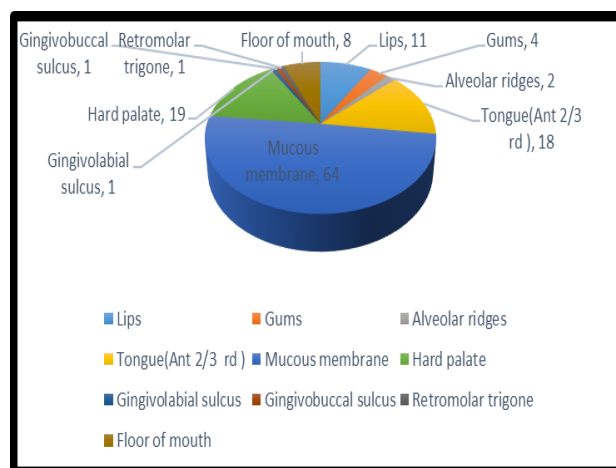
In our study, the most common cause for ulceromembranous lesions in oral cavity was aphthous ulcer which accounts for 15%. Neoplastic conditions altogether constitute 27% of total cases, among which carcinoma tongue was most common followed by floor of mouth, lips and buccal mucosa. Carcinoma tongue accounts to 14%, carcinoma floor of mouth constitute 6%. Traumatic etiology accounts to 12%.

22 patients among 100 study subjects had history of risk factors such as smoking and 13 with alcoholism. Among

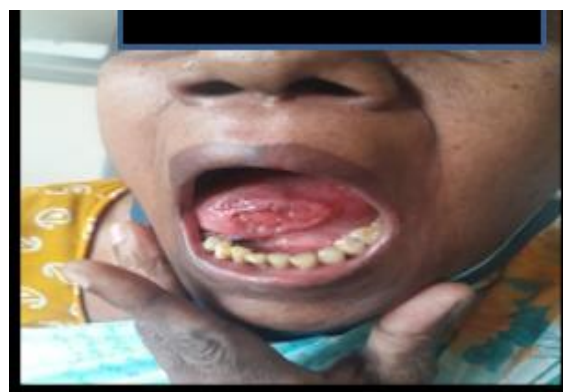100 patients highest number of patients 39 gave history of tobacco chewing.

**Table 6: Distribution of cases according to outcome.**

Outcome	Number
Improved	46
Recovered	42
Unchanged	7
Worsened	1
Expired	2



**Figure 1: Distribution of cases according to site of lesion.**



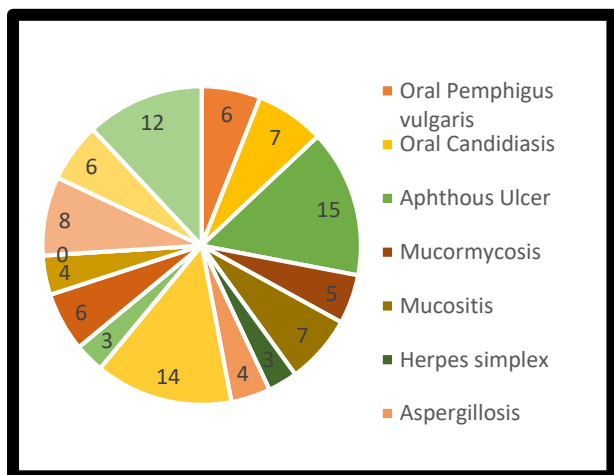
**Figure 2: Carcinoma tongue.**

History of alcohol intake was present in 13 patients and 8 patients had history of both smoking and alcohol. 48 did not have any risk factors. Out of 27 patients with malignant ulcers, smoking, alcohol, history was present in 8 patients, history of alcohol intake was present in 13 patients and history of both smoking and alcohol intake was present in 6 patients.

## DISCUSSION

Local reasons (bacterial or viral), systemic disorders, drug-related reactions, or lifestyle variables such as

tobacco, betel-quid, and alcohol usage can all produce oral ulceromembranous lesions. During the study period, ulcero-membranous lesions in the oral cavity accounted for 0.45 percent of the cases examined in ENT services.



**Figure 3: Distribution of cases according to diagnosis.**

The most typically affected age group for ulcero-membranous lesions in the oral cavity was 36-55 years (57 percent), which is also same according to a study published in 2008 by Isaac U and Isaac JS et al. The study's youngest patient was a 22-year-old boy, and the oldest patient was a 65-year-old man.

Most common site affected in our study is mucous membrane followed by hard palate and then tongue. In our study, the most common cause for ulcero-membranous lesions in oral cavity was aphthous ulcer which accounts for 15%. Neoplastic conditions altogether constitute 27% of total cases, among which Carcinoma tongue was most common followed by floor of mouth, lips and buccal mucosa. Carcinoma tongue accounts to 14%, carcinoma floor of mouth constitute 6%. Traumatic etiology accounts to 12%. 8 patients. Among 100 patients highest number of patients (39) gave history of tobacco chewing. 13 patients had a history of alcohol consumption, and 8 patients had both a smoking and an alcohol consumption history. 48 patients out of a total of 100 had no risk factors. Tobacco chewing history was found in 26 of the 27 patients with malignant ulcers, history of alcohol intake was present in 13 patients, and history of both smoking and alcohol intake was present in 8 patients. In our study, 68 patients (68%) were treated conservatively. Six (six percent) of the 27 patients with malignant ulcers chose radiotherapy, while one patient with a malignant ulcer had both radiotherapy and surgical treatment. Most of the patients showed improvement following treatment (46%), 42% fully recovered and 2 patients with Carcinoma buccal mucosa expired due to complications.

All 27 patients who presented with malignant ulcers had history of either tobacco usage (smoking/tobacco chewing) or alcohol consumption for more than 10 years

which is also seen in studies by Isaac et al, Saintrain et al and Phelan et al.<sup>4,6</sup> The most common symptoms in our study were ulcero-membranous lesions in the oral cavity and discomfort followed by pain and burning sensation.

Infectious disease was the most common cause of ulcero-membranous lesions in the oral cavity (44.62 percent), followed by inflammatory disease (29.23 percent). Thimmappa et al and Goyal et al found that 50 percent of the cases were caused by inflammation.<sup>9,10</sup> Diphtheria was the most prevalent bacteria recovered from ulcero-membranous lesions in the oral cavity and oropharynx, according to Sridhar et al.<sup>7</sup>

Recurrent aphthous stomatitis was detected in 15 patients, the majority of which were between the ages of 25 and 55, with a female preponderance (F:M=2:1). There were no predisposing variables in 11 of the 15 patients. Crispian et al and Goyal et al showed that recurrent aphthous ulcers were the most common entity, accounting for almost half of all cases.<sup>8,9</sup>

Malignant ulcers in the oral cavity accounted for about 27% in our study, which is similar to Manjunath et al and Mahavar et al.<sup>11</sup>

Studies by Thimmappa et al shows only 6.5% were malignant.<sup>10</sup> The most common site of malignancy in oral cavity in this study was tongue followed by floor of mouth and lips. Study done by Mathur et al showed that the most common site was buccal mucosa.<sup>12</sup>

Malignant ulcers (27 out of 100 subjects) were most commonly seen in the age group of 40-65 years in female patients. In this study, female preponderance (14 female patients out of 27 patients with malignant ulcers) was found in patients having malignant ulcers, which is comparable to study by Saintrain et al showed female preponderance of oral malignant lesions.<sup>5</sup>

Studies done by Thimmappa et al, Manjunath et al, Isaac et al showed male preponderance.<sup>10,11,16</sup> Only 13 male patients were encountered in malignant ulcer group in our study.

Miscellaneous causes for ulcero-membranous lesions in oral cavity found in our study were oral pemphigus vulgaris (6), leukoplakia (8), mucositis (7), oral candidiasis (7), mucormycosis (5), herpes simplex (3), aspergillosis (4), fixed drug eruption (6). These are seen most commonly in the age group of 36-55 years with male to female ratio of 7:9.

In our study 68 out of 100 cases were managed conservatively. Patients with recurrent aphthous stomatitis were treated symptomatically with multivitamins, antioxidants, antacids, topical anaesthetic agents, and antiseptic gargling solution.<sup>3</sup> Patients with viral etiology were treated with oral acyclovir and topical anesthetic agents. 7 patients with oral candidiasis were treated with

oral fluconazole, topical clotrimazole and topical antiseptic gargling solution. 6 patients received radiotherapy and 21 patients underwent surgery. Studies by Crispian et al and Patil et al also shows that majority of them were managed conservatively.<sup>13,14</sup>

In a prospective study of 60 patients with ulcero-membranous lesions in the oral cavity and oropharynx, Thimmappa et al discovered that 50% of cases were non-specific ulcers, 15% were aphthous ulcers, 8.3% were traumatic ulcers, 6.5 percent were malignant ulcers, 6.5 percent were dental ulcers, 3.2 percent were HIV infection and AIDS, 3.2 percent were tuberculosis ulcers, and 6.5 percent Low socioeconomic position, lack of education, poor dental hygiene, and unhealthy habits formed in childhood are all predisposing factors, according to the author. As a result, in all cases of ulcers, early identification and treatment are recommended.<sup>10</sup>

In India, Mehta et al studied the epidemiology and histology of oral cancer and leukoplakia in 50,915 villagers. Patients were chosen based on the types of chewing and smoking behaviours they had. The prevalence of epithelial atypia ranged from 3.0 percent to 12.4 percent in biopsies from 723 leukoplakias, according to histological analyses. Epithelial atypia was observed in 8.4% of homogeneous leukoplakias and 59.1% of speckled leukoplakias. The author found that leukoplakia was the most frequent precancerous oral lesion in India, with speckled form leukoplakia being more likely to progress to malignancy.<sup>15</sup>

### Limitations

Relative risk and attributable risk of smoking, tobacco chewing and alcohol consumption for malignant ulcers needs to be calculated in two separate cohort groups with or without malignant ulcers. Long term follow up needs to be done to determine the frequency of recurrence, predisposing factors and evaluation of recurrent aphthous stomatitis.

### CONCLUSION

A descriptive study of ulcero-membranous lesions in oral cavity presenting to ENT department from November 2019 to May 2021 was done. In this study out of 22147 patients who attended ENT OPD during study period, 100 patients presented with ulcero-membranous lesions in oral cavity which accounted for 0.45%. Mostly females of the age group 36 to 45 years were affected in our study. A variety of etiological factors were found in these patients with ulcero-membranous lesions in oral cavity, the foremost being malignant in nature, which accounted for 27%, followed by inflammatory etiology (22%). In infective etiology ulcero-membranous lesions caused by fungus were most common (11%), and viral infection constitute 3%. If considering single most common condition, recurrent Aphthous ulcer is the most common condition seen in our study. In our study, patients

presented with ulcerative lesion in oral cavity and pain were the most common complaints. History of tobacco chewing was present in majority of patients with malignant lesions. Most of the patients (conservative management-68%) were treated symptomatically with oral and topical agents. 21 patients were treated surgically and 6 patients received radiotherapy.

### ACKNOWLEDGEMENTS

The authors are thankful to Dr. S.V. Divakar, MD, Principal, DR B. R. Ambedkar Medical College and Hospital, Bangalore for permitting the use of the facilities in the college.

*Funding: No funding sources*

*Conflict of interest: None declared*

*Ethical approval: The study was approved by the Institutional Ethics Committee*

### REFERENCES

1. Garber A, Klein E, Bruce S, Sankoh S, Mohideen P. Metformin-glibenclamide versus metformin plus rosiglitazone in patients with type 2 diabetes inadequately controlled on metformin monotherapy. *Diabetes Obes Metab.* 2006;8(2):156-63.
2. O'Brien C. Drug addiction and drug abuse. In: Brunton LB, Lazo JS, Parker KL, eds. *Goodman & Gilman's The Pharmacological Basis of Therapeutics.* 11th ed. New York, NY: McGraw-Hill. 2005;607-29.
3. National Cancer Institute. Fact sheet: targeted cancer therapies, 2012. Available at: <http://www.cancer.gov/cancertopics/factsheet/Therapy/targeted#q1>. Accessed on 9 June 2014.
4. Saintrain MV, Holanda TG, Bezerra TM, de Almeida PC. Prevalence of soft tissue oral lesion in elderly and its relations with deleterious habits. *Gerodontology.* 2012;29(2):130-4.
5. Phelan JA, Eisig S, Freedman PD. Major aphthous like ulcers in patients with AIDS. *Oral Surg Oral Med Oral Pathol.* 1991;71(1):68-72.
6. Mahawar P, Anand S, Sinha U. Screening for pre-malignant conditions in the oral cavity of chronic tobacco chewers. *National Journal of Community Medicine.* 2011;2(1):82-5.
7. Mortazavi H, Safi Y, Baharvand M, and Rahmani S. Diagnostic Features of Common Oral Ulcerative Lesions: An Updated Decision Tree. *International Journal of Dentistry.* 2016;7278925.
8. Santosh P, Nidhi Y, Prashant P, Sumita K. Prevalence and the relationship of oral mucosal lesions in tobacco users and denture wearers in the North Indian population. *J Family Community Med.* 2013;20(3):187-91.
9. Sridhar RD, Shoban BA. Study of Ulcero-membranous Lesions of Tonsil in an Indian scenario. *Indian J Otolaryngol Head Neck Surg.* 2017;69(1):16-9.

10. Thimmappa TD. A study on the clinical profile of ulcers and membranous lesions of oral cavity and oropharynx. *Int J Res Med Sci.* 2014;2(1):180-5.
11. Isaac U, Issac JS, Khoso NA. Histopathologic features of oral submucous fibrosis: a study of 35 biopsy specimens. *Oral Surg Oral Med Oral Pathol Oral Radiol Endod.* 2008;106(4):556-60.
12. Zakrzewska JM, Robinson P, Williams IG. Severe oral ulceration in patients with HIV infection: a case series. *Oral Dis.* 1997;3(1):S194-6.
13. Sujatha RS, Rakesh N, Deepa J, Ashish L, Shridevi B. Rhino cerebral mucormycosis. A report of two cases and review of literature. *J Clin Exp Dent.* 2011;3:256-60.
14. Aggarwal P, Saxena S, Bansal V. Mucormycosis of maxillary sinus. *J Oral Maxillofac Pathol.* 2007;11:66-9.
15. Mehta FS, Pindborg PP, Gupta PC. Epidemiologic and histologic study of oral cancer and leukoplakia among 50,915 villagers in India. *J American Cancer Society.* 1969;24(4):832-49.

**Cite this article as:** John S, Muniraju M, Sreekala SS, Julie PR. A clinical study and management of ulceromembranous lesions of oral cavity. *Int J Otorhinolaryngol Head Neck Surg* 2022;8:144-9.