

## Case Report

# Combined modality therapy for naso-oropharyngeal solitary extramedullary plasmacytoma: case report

Andrea Masarykova\*, Marin Dzongov, Alexandra Hanicova,  
Ingrid Zavacka, Danijela Scepanovic

Department of Radiation Oncology, National Cancer Institute of Slovakia, Bratislava, Slovakia, Europe

**Received:** 17 July 2017

**Revised:** 29 August 2017

**Accepted:** 31 August 2017

### \*Correspondence:

Dr. Andrea Masarykova,

E-mail: [andrea.masarykova@gmail.com](mailto:andrea.masarykova@gmail.com)

**Copyright:** © the author(s), publisher and licensee Medip Academy. This is an open-access article distributed under the terms of the Creative Commons Attribution Non-Commercial License, which permits unrestricted non-commercial use, distribution, and reproduction in any medium, provided the original work is properly cited.

## ABSTRACT

Most patients with plasma cell neoplasia have generalized disease at diagnosis. However, some patients have a solitary extramedullary plasmacytomas (SEPs). SEPs are rare, typically solitary tumors comprising approximately 3–5% all plasma cell neoplasms. Almost 90% arise in the head and neck region, especially in the nasal cavity, sinuses, oropharynx, salivary glands and larynx. Solitary extramedullary plasmacytoma (SEP) has a predilection for the male gender and occurs most frequently in patients 50 years and older. SEP often runs an indolent clinical course with a tendency for local recurrence, and progresses to plasma cell myeloma in about 15% of patients. In this paper, we have reported the case of SEP of the naso-oropharynx in 55 years old woman who was presented with a sense of the nasal obstruction. The resection was performed and a mature plasmacytoma was demonstrated histologically. However, ENT examination and positron emission tomography/computed tomography examination with 18-fluorodeoxyglucose (18-FDG PET/CT) have shown that the patient had residual naso-oropharyngeal disease after surgery. A negative bone marrow biopsy and 18-FDG PET/CT have confirmed that it was a solitary extramedullary plasmacytoma of the head and neck region. Following the surgery, intensity modulated radiotherapy (IMRT) was administered. No relapse or progression to the multiple myeloma was recorded during the 3.5 years of follow-up. This case report, which describes a rare tumor of the naso-oropharynx, is expected to improve the recognition and referral of this condition in medical practice.

**Keywords:** Naso-oropharynx, Extramedullary plasmacytoma, Surgery, Radiotherapy

## INTRODUCTION

Solitary plasmacytomas (SPs) most frequently occur in bone, but can also be found outside bone in soft tissues (extramedullary plasmacytomas - EMPs). They are solitary lesions, and are most often located in the head and neck region, mainly in the upper aerodigestive tract, but may also occur in the gastrointestinal tract, urinary bladder, central nervous system, thyroid, breast, testes, parotid gland, lymph nodes, and skin.<sup>1</sup>

Solitary extramedullary plasmacytomas (SEPs) are extremely rare tumors that arise outside of the bone marrow in the absence of any sign of multiple myeloma.<sup>2</sup> They are typically solitary tumors comprising approximately 3–5% all plasma cell neoplasms. Almost 90% arise in the head and neck region, especially in the nasal cavity, sinuses, oropharynx, salivary glands and larynx. SEP has a predilection for the male gender and occurs most frequently in patients 50 years and older.<sup>1</sup>

Genetic factors, radiation exposure, smoking, occupational exposures, chronic stimulation caused by

inhaled irritants or viral infection have been implicated as possible etiologic agents.<sup>3</sup>

In a series of 20 patients with extramedullary plasmacytoma of the head and neck, Kapadia and colleagues observed the following major symptoms: tumor or local edema in 80%, nasal obstruction in 35%, epistaxis in 35%, localized pain in 20%, proptosis in 15%, rhinorrhea in 10%, regional lymphadenopathy in 10%, and paralysis of the VI cranial nerve in 5% of cases.<sup>4,5</sup> The diagnosis of extramedullary plasmacytoma depends initially on clinical suspicion. For most patients the diagnosis can be established by fine needle aspiration or biopsy. Computed Tomography scanning or Magnetic Resonance Imaging is required to delineate the extent of the lesion.<sup>6,7</sup>

The optimal management of SEPs is controversial. SEPs should be treated by radical radiotherapy. Surgery is generally not required for diagnosis of SEPs in the head and neck region due to the mutilating nature of surgical procedures and high radiosensitivity of SEPs.<sup>1</sup> The role of chemotherapy in SEPs is not well-defined.<sup>8</sup>

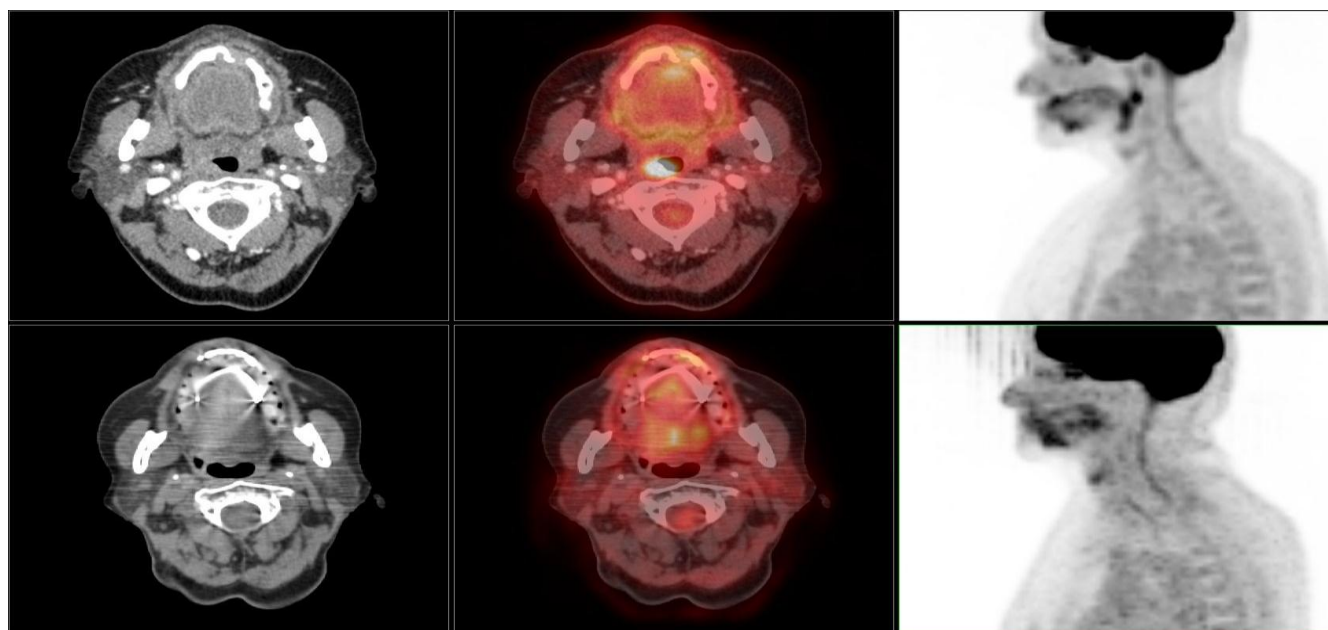
Local recurrence rate of <5% have been quoted after radiotherapy. The risk of distant relapse appears to be <30%. When distant relapse occurs this tends to be within 2-3 years of initial diagnosis.<sup>1</sup> At least two-thirds of patients survive for >10 years.<sup>9</sup>

## CASE REPORT

EB, 55-year-old woman had a progressive nasal obstruction for a long time. Due to a respiratory infection, the patient visited a general practitioner who had noticed

"a strange finding" in the pharynx during the examination. Thereafter, she presented to an otorhinolaryngology service in February 2014 with suspicion of a hemangioma or hypertrophy of lymphoid tissue in the nasopharynx. On 20<sup>th</sup> February 2014, a resection was performed and the mature plasmacytoma was histologically diagnosed. The immunohistochemical assays demonstrated Kappa chain positive, Lambda chain negative, and CD56 negative.

After resection the ENT examination by the fiberscope showed: nasopharynx was free, at the site of resection on the back of nasopharynx the mucus was presented, also under the left torus tubarius, an irregular mucosa was under the right torus tubarius, clinically it looked like lymphatic tissue, it was obviously a residual disease. Thereafter, the patient was presented to the clinical oncologist at National Cancer Institute for a further consultation. Result of flow cytometry examination was: in the examined bone marrow sample, we did not find a relevant quantifiable amount of CD38+, CD138+ elements, therefore bone marrow involvement with myeloma was very unlikely. Cytogenetic examination using the Easy Sep kit was not separated CD138+ cells. Trephine biopsy of the bone marrow was negative. Urine and plasma electrophoresis were performed following the histological diagnosis, revealing no evidence of monoclonal band. There was no anemia, hypercalcemia or renal impairment caused by plasma cell dyscrasias. Clinical oncologist recommended a 18-FDG PET/CT scan to exclude systemic disease what the patient underwent on 3<sup>rd</sup> April 2014. The 18-FDG PET/CT scan showed: irregularly thickening of the right and dorsal pharynx walls at the naso and oropharynx interface, with pathological metabolic activity (SUV max 8.20) (Figure 1).



**Figure 1: Initial 18-FDG PET/CT with residual naso-oropharyngeal tumor after surgery (top row) and last 18-FDG PET/CT without tumor evidence (bottom row).**

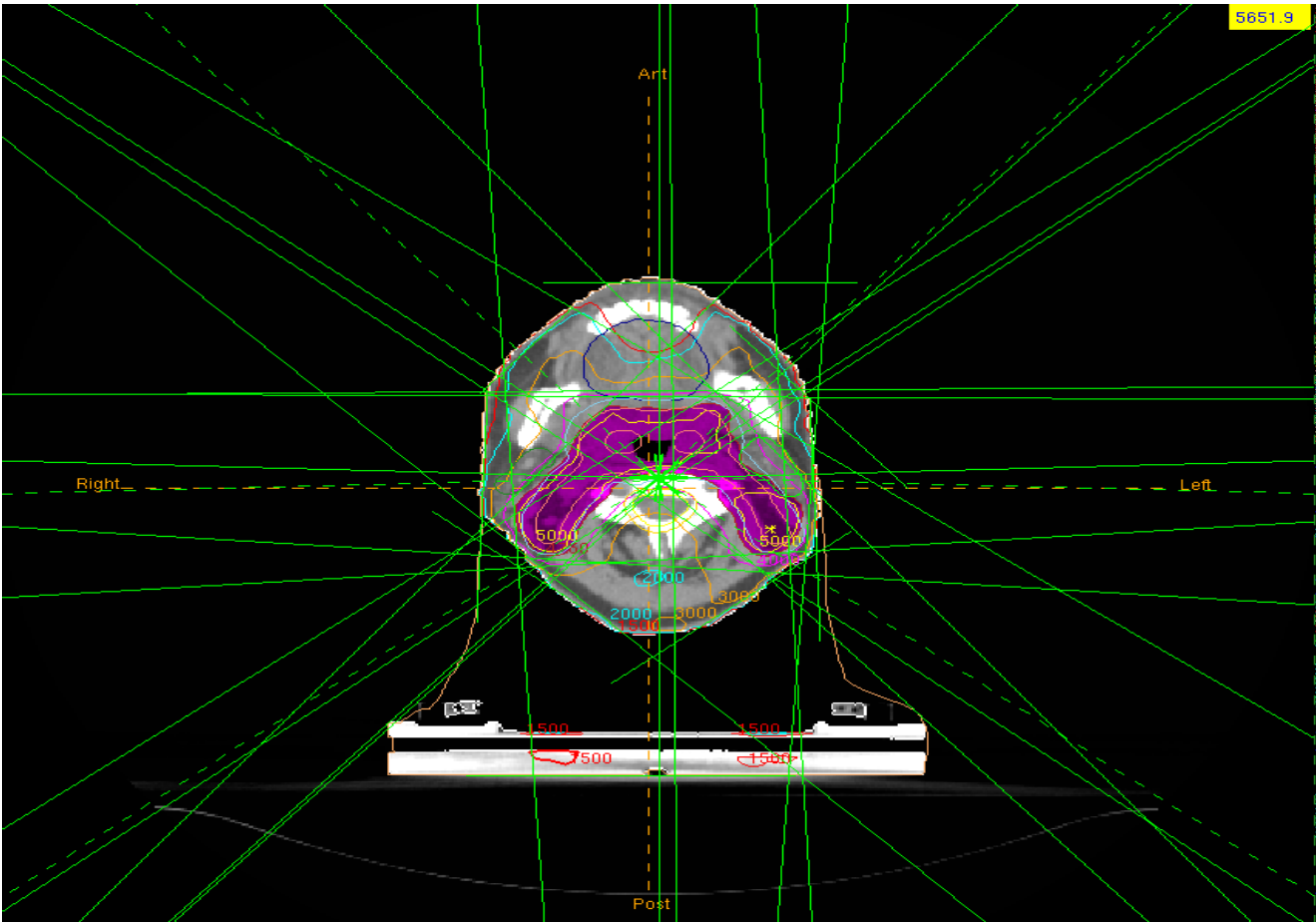


Figure 2: IMRT “step and shoot” technique– dose distribution.

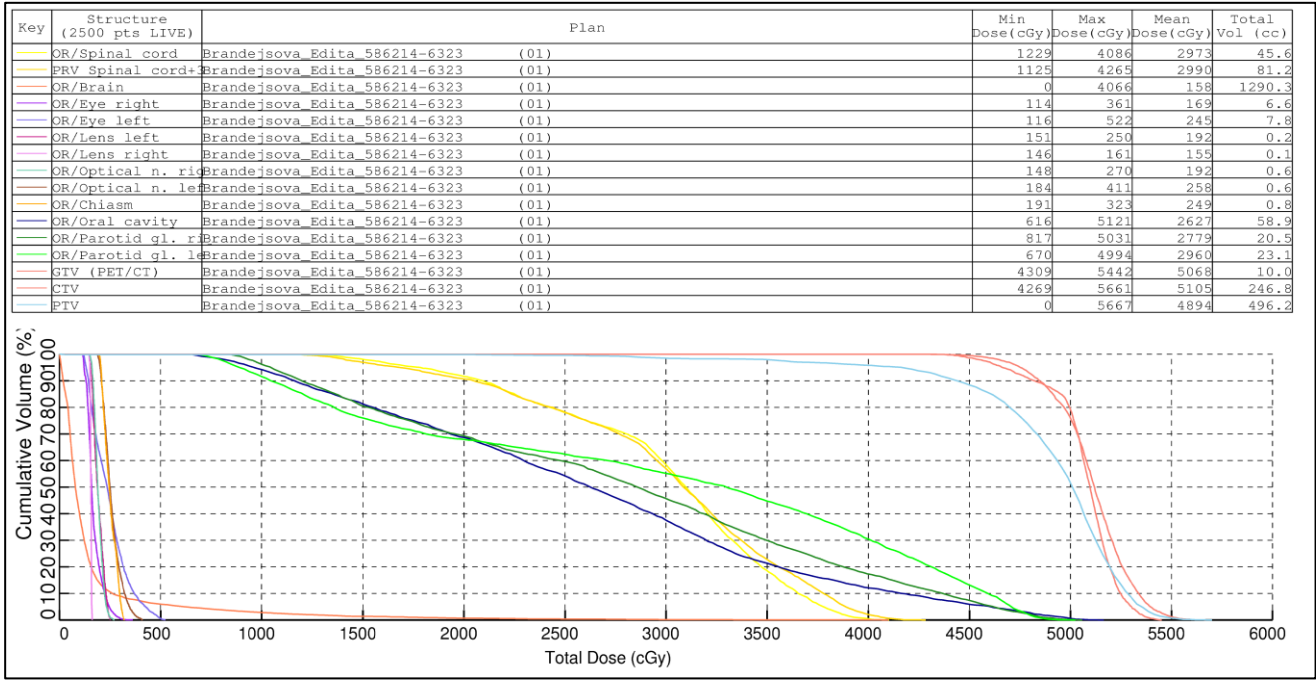


Figure 3: Maximum doses to specific organs at risk and DVH.

According to the all investigations, it was concluded that it was SEP and the patient was referred to our department of radiation oncology. We planned IMRT of the naso-oropharynx and levels II to V of cervical lymph nodes, also, retropharyngeal space what the all was included in clinical target volume (CTV). The lymph node levels were outlined according to the guidelines of Gregoire et al. Target definition was in accordance with the developed guidelines for IMRT of head and neck cancer developed by the Danish head and neck cancer group (DAHANCA). Treatment planning was based on the fusion of 18-FDG PET/CT and CT scans for planning with slices thickness of 3 mm. The patient was treated on a carbon couch positioned by an individual mask covering the head and shoulders. The energy used for this treatment was 6 MV X-ray. IMRT plan was calculated using Oncentra v4® (Nucletron, an Elekta company, Elekta AB, Stockholm, Sweden). Planning target volume (PTV) was created by adding a margin of 5 mm corresponding to our possible set-up error. Treatment was delivered by a linear accelerator (Elekta Synergy; Elekta AB) with multileaf collimator - MLC (80 leaves, 40 × 40). Eight gantry angles were used (0°, 50°, 88°, 140°, 180°, 220°, 272°, 310°) by the IMRT “step and shoot” technique (Figure 2). We prescribed a total radiation dose of 50.4 Gy in 28 fractions, 5 fractions per week.

Maximum doses to specific organs at risk and DVH (dose volume histogram) were listed in Figure 3.

After the fifteen days of radiotherapy treatment, the patient had difficulty as nausea, vomiting, and she could not eat and drink. A nasogastric probe was introduced, the patient was hospitalized and radiotherapy was discontinued for 7 days.

An ENT examination with a fibroscope showed that in the nasopharynx on the right side there was a still positive tissue at the site under the torus tubarius, however, it was smaller than previously; on the left side the mucous membrane was smooth, without any pathology.

After the break, patient continued planned radiotherapy treatment and finished it on 3<sup>rd</sup> July 2014.

At the first ENT check, 2 months after finishing of the radiotherapy, the patient had dryness in the oral cavity and pharynx; also, she had a sore throat. During the radiotherapy she lost in weight for about 12 kg. Findings by the fibroscope were: on the back wall in the level of soft palate on the right side there was a positive tissue under the torus tubarius but smaller than before therapy. A biopsy was taken and the histological finding showed extensive solid infiltrates with plasmacytoma. Nothing was advised, just follow-up. Six months after biopsy, we made the new 18-FDG PET/CT scan that was showed the complete regression of the previously metabolically active changes in the naso-oropharynx interface. The patient has been followed-up regularly, every 3 months

by the ENT specialist and haematologist. In July 2017, we repeated the 18-FDG PET/CT examination (Figure 1).

The disease was under the control, without relapse or progression to the multiple myeloma for the period of 3.5 years after diagnosis. The patient was well; however, the mouth dryness persisted.

## DISCUSSION

SEPs account for only 1% of all tumors of head and neck region and only 4% of all nonepithelial tumor of the nasal tract. Typical location of SEPs in head and neck region are pharynx (21.5%), nasal cavity (19.3%), oral cavity (14.7%) and paranasal sinus (13.0%). Male to female ratio are 2:1. The median age of patients with SEPs is 55 years.<sup>10, 11</sup> Our patient was 55-year-old woman who had naso-oropharyngeal solitary extramedullary plasmacytoma.

Most of the symptoms related to extramedullary plasmacytoma can be related to their specific location in the head and neck. Cervical lymph node metastasis is reported to occur in 12-26% of cases at initial presentation.<sup>12</sup> Our patient had a progressive nasal obstruction for a long time, and no cervical lymph nodes involvement.

Because extramedullary plasmacytoma is rare, the first diagnosis of these tumors is usually a malignant tumor hypothesized to be squamous cell carcinoma since the clinical presentation of these entities is similar. Histopathological analysis cannot distinguish a multiple myeloma from an extramedullary plasmacytoma, and further evaluation should be performed to rule out systemic disease. It is also necessary to perform the additional tests to make the differential diagnosis from other malignant tumors (melanoma, undifferentiated carcinoma, pituitary adenoma, and others).<sup>4</sup> The diagnosis of SEP of the naso-oropharynx in our patient has been based on the following criteria: (a) pathological tissue evidence of monoclonal plasma cells involving a single extramedullary site, (b) no bone marrow involvement, (c) negative 18-FDG PET/CT, (d) no anemia, hypercalcemia or renal impairment caused by plasma cell dyscrasias and (e) low serum and urinary levels of monoclonal immunoglobulin.

The workup and definition of a solitary plasmacytoma as well as its risk of progression to multiple myeloma has been well defined, and PET/CT scans have emerged as an important modality that helps confirm diagnoses and leads to definitive therapy in at least some cases.<sup>13</sup> A PET/CT scan can provide a fast, whole-body modality with a sensitivity of 96%, specificity of 77% and a particular advantage of detecting extramedullary disease.<sup>14,15</sup> Current recommendations include CT or MRI scanning to delineate the extent of the lesion at the head and neck region but the role of MRI scanning of others areas in the staging of SEP has not be evaluated.<sup>1</sup> Despite



the fact that there are no specific published guidelines for diagnosis of a SEP or on how to perform surveillance in patients with plasmacytomas, we used 18-FDG PET/CT to exclude the systemic disease, thereafter for surveillance, as well as for planning of radiotherapy treatment. This examination seemed to be simple, multifunctional and reliable, however, only in combination with the others diagnostic methods.

There is no good evidence that surgery offers any additional benefit over radiotherapy alone in patients with SEP of the head and neck. Radiotherapy alone is curative in the vast majority of patients. However, if patients have been treated by primary surgery, radiotherapy would only be required in patients with inadequate surgical margins.<sup>1</sup> As it was with our patient.

SEPs are highly radiosensitive tumours. Local control rates of 80-100% are consistently reported. There is no firmly established dose-response relationship, because of small patient series and low local failure rates. SEP <5 cm have an excellent chance of local control with radiation doses in the region of 40Gy in 20 fractions, whereas there is a higher risk of local failure in tumours >5 cm, which require a higher dose in the region of 50 Gy in 25 fractions.<sup>16</sup> We decided for a higher dose of 50.4 Gy in 28 fractions, because a residual tumor in naso-oropharynx was presented after surgical resection.

The optimal radiotherapy target volume is similarly controversial. SEPs arising in the upper gastro-intestinal or respiratory tract (>80% of cases) metastasize to cervical lymph nodes in 10-40% of cases. The inclusion of draining cervical nodes in the radiation fields significantly adds to acute and late morbidity, especially xerostomia, which may not fully recover.<sup>17-19</sup> Due to a small number of patients with SEP, the current recommendations are controversial. We did not have the initial tumor size because the patient performed surgery at the other hospital and this information was not recorded there. Due to a residual tumor after surgery, we assumed that it was a large tumor before. Also, the residual tumor was the reason why we electively included the cervical lymph nodes to the CTV, although the risk of xerostomia was increased, as the case with our patient was.

The role of chemotherapy in SEPs is not well-defined.<sup>8</sup> Adjuvant chemotherapy should be considered in patients with tumours >5 cm and those with high grade tumours. Chemotherapy is indicated for patients with refractory and/or relapsed disease.<sup>1</sup> Chemotherapy was not indicated to our patient by the clinical oncologist.

Two months after completion of radiotherapy the residual disease was recorded what it could be caused with slow regression of the tumor treated with radiotherapy. Thereafter, patient was observed and monitored periodically and clinically did not show any evidence of residual or systemic disease.

## CONCLUSION

Because of the high rate of recurrence and progression to multiple myeloma, follow-up radiological and electrophoresis assessment is required following treatment. This case report, which describes a rare tumor of the naso-oropharynx, is expected to improve the recognition and referral of this condition in medical practice.

## ACKNOWLEDGMENTS

Our thanks go to the staff of Radiation Oncology Department of National Cancer Institute of Slovakia in Bratislava.

*Funding: No funding sources*

*Conflict of interest: None declared*

*Ethical approval: The study was approved by the Institutional Ethics Committee*

## REFERENCES

1. Soutar R, Lucraft H, Jackson G, Reece A, Bird J, Low E, et al. Guidelines on the diagnosis and management of solitary plasmacytoma of bone and solitary extramedullary plasmacytoma. *Br J Haematol.* 2004;124(6):717.
2. Merza H, Sarkar R. Solitary extrasosseous plasmacytoma- case report. *Clin Case Rep.* 2016;4(9):851-4.
3. Abdullah AM, Ibrahim Z, Yusuf Z, Ramli RR. An Extramedullary Plasmacytoma of the Nasopharynx: A rare entity. *Bangladesh J Med Sci.* 2016;15:477-9.
4. Corvo dos Anjos MA, Granato L, Ikeda F, de Prospero JD. Extramedullary nasal plasmacytoma: Literature review and a rare case report. *Int Arch Otorhinolaryngol.* 2013;17(2):213-7.
5. Kapadia SB, Desai U, Cheng VS. Extramedullary plasmacytoma of the head and neck. A clinicopathologic study of 20 cases. *Medicine.* 1982;61(5):317-29.
6. Baur A, Stabler A, Nagel D, Lamerz R, Bartl R, et al. Magnetic resonance imaging as a supplement for the clinical staging system of Durie and Salmon? *Cancer.* 2002;95(6):1334-45.
7. Ching AS, Khoo JB, Chong VF. CT and MR imaging of solitary extramedullary plasmacytoma of the nasal tract. *AJNR Am J Neuroradiol* 2002;23:1632-6.
8. Maheshwari A, Panigrahi R, Mahajan S. Solitary Extramedullary Plasmacytoma of Nasal Cavity: An Emerging Differential Diagnosis of Nasal Masses. *Int J Sci Study.* 2016;3(11):178-81.
9. Galieni P, Cavo M, Pulsoni A, Avvisati G, Bigazzi C, Neri S, et al. Clinical outcome of extramedullary plasmacytoma. *Haematologica.* 2000;85:47-51.
10. Daniel G, Eric J. Epidemiologic Evidence of Superior Outcomes for Extramedullary Plasma-

- cytoma of the Head and Neck. *Otol Head Neck Surg.* 2013;148:974-81.
11. Produl H, Balakrishnan R, Rohit S, Kailesh P, Benazim A. Solitary Extramedullary Plasmacytoma of the Sinonasal Region. *Ind J Otol Head Neck Surg.* 2011;63:33-5.
  12. Azman M, Gendeh BS, Mat Ali SA. Extramedullary Plasmacytoma of the Nasopharynx: A Rare Tumour with 7-Year Follow Up. *Philipp J Otolaryngol Head Neck Surg.* 2011;26(1):27-30.
  13. Rajkumar SV, Dimopoulos MA, Palumbo A, Blade J, Merlini G, Mateos MV, et al. International Myeloma Working Group updated criteria for the diagnosis of multiple myeloma. *Lancet Oncol.* 2014;15(12):538-48.
  14. Lu YY, Chen JH, Lin WY, Liang JA, Wang HY, Tsai SC, et al. FDG PET or PET/ CT for detecting intramedullary and extramedullary lesions in multiple Myeloma: a systematic review and meta-analysis. *Clin Nuclear Med.* 2012;37(9):833-7.
  15. Gautam A, Sahu KK, Alamgir A, Siddiqi S, Ailawadhi S. Extramedullary Solitary Plasmacytoma: Demonstrating the Role of 18F-FDG PET Imaging. *J Clin Diagnostic Res.* 2017;11(4):1-3.
  16. Michalaki VJ, Hall J, Henk JM, Nutting CM, Harrington KJ. Definitive radiotherapy for extramedullary plasmacytomas of the head and neck. *British J Radiol.* 2003;76:738-41.
  17. Hu K, Yahalom J. Radiotherapy in the management of plasma cell tumors. *Oncology (Willston Park).* 2000;14(1):101-8.
  18. Tsang RW, Gospodarowicz MK, Pintilie M, Bezjak A, Wills W, Hodgson DC, et al. Solitary plasmacytoma treated with radiotherapy: impact of tumor size on outcome. *Int J Radiat Oncol Biol Phys.* 2001;50(1):113-20.
  19. Gregoire V, Levendag P, Ang KK, Bernier J, Braaksma M, Budach V, et al. CT-based delineation of lymph node levels and related CTVs in the node-negative neck: DAHANCA, EORTC, GORTEC, NCIC, RTOG consensus guidelines. *Radiother Oncol.* 2003;69:227-36.

**Cite this article as:** Masarykova A, Dzungov M, Hanicova A, Zavacka I, Scepanovic D. Combined modality therapy for naso-oropharyngeal solitary extramedullary plasmacytoma: case report. *Int J Otorhinolaryngol Head Neck Surg* 2017;3:1105-10.